

1-1-2011

Bilateral testicular hypoplasia among mature Sahel bucks in Nigeria

IKECHUKWU IGBOKWE

AUGUSTINE IKPO

HAFSAT GREMA

FAKILAHYEL MSHELBWALA

NANACHA IGBOKWE

Follow this and additional works at: <https://journals.tubitak.gov.tr/veterinary>



Part of the [Animal Sciences Commons](#), and the [Veterinary Medicine Commons](#)

Recommended Citation

IGBOKWE, IKECHUKWU; IKPO, AUGUSTINE; GREMA, HAFSAT; MSHELBWALA, FAKILAHYEL; and IGBOKWE, NANACHA (2011) "Bilateral testicular hypoplasia among mature Sahel bucks in Nigeria," *Turkish Journal of Veterinary & Animal Sciences*: Vol. 35: No. 2, Article 8. <https://doi.org/10.3906/vet-0909-108>

Available at: <https://journals.tubitak.gov.tr/veterinary/vol35/iss2/8>

This Article is brought to you for free and open access by TÜBİTAK Academic Journals. It has been accepted for inclusion in Turkish Journal of Veterinary & Animal Sciences by an authorized editor of TÜBİTAK Academic Journals. For more information, please contact academic.publications@tubitak.gov.tr.

Bilateral testicular hypoplasia among mature Sahel bucks in Nigeria

Ikechukwu O. IGBOKWE^{1*}, Augustine E. IKPO¹, Hafsat A. GREMA¹,
Fakilahyel M. MSHELBWALA¹, Nanacha A. IGBOKWE²

¹Department of Veterinary Pathology, Faculty of Veterinary Medicine, University of Maiduguri,
P.M.B. 1069, Maiduguri - NIGERIA

²Department of Veterinary Physiology and Pharmacology, Faculty of Veterinary Medicine,
University of Maiduguri, P.M.B. 1069, Maiduguri - NIGERIA

Received: 30.09.2009

Abstract: Among 1608 Sahel goat bucks presented for slaughter at the Maiduguri Metropolitan abattoir in March-April 2007, 65.7% had plain white or black-white coat colour, and 91.2% were aged >1.5-3.0 years with mean body weights of 15.6-25.7 kg. Twenty-two (1.4%) of the mature bucks, aged 1.9 ± 0.3 years and weighing 20.6 ± 3.5 kg, had bilateral small hypoplastic testes that were symmetric, approximately 7 times smaller in weight, with a 2-fold reduction in longitudinal length and mid-circumference than the full-sized normal testes. The epididymes were also reduced in size as the testes. Histologically, the seminiferous tubules and caudal epididymides showed no evidence of spermatogenesis and the basement membranes of the seminiferous tubules were smooth. This is first report of bilateral testicular hypoplasia among Sahel goats in Nigeria.

Key words: Nigerian Sahel goats, population at slaughter in abattoir, testicular hypoplasia, testicular symmetry, small-sized testes

Introduction

There are 446 million goats in the world, 144.7 million of which are found in Africa (1). In Nigeria, there are about 34.5 million goats consisting of Sahel, Sokoto Red (Maradi), and the West African Dwarf breeds (2). The breeds are recognised by their physical appearance and grouped according to geographical distribution. Sahel goats are found in the Sahel belt of northern Nigeria, where arid and semi-arid weather conditions prevail. They are long-legged with short fine coat hairs and principal coat colours of plain white, black, brown, or the combinations of these colours in patches or spots (3,4).

The mature body weight of an animal is the mean weight where positive muscular and skeletal growth

* E-mail: ikeigbokwe@gmail.com

has reached a plateau (5). Testicular size is an integral component of body size and could be extrapolated from one another because of their correlation (6). Male reproduction depends on sperm production, which is related to testicular size (7-11). Abnormally small hypoplastic testes, associated with impaired reproductive capacity, occur as a result of the failure of the testes to develop to normal size in a mature animal and may be caused by prepubertal malnutrition, and hereditary and endocrine factors (12).

Bilateral testicular hypoplasia is hereby reported for the first time among a characterised population of Nigerian Sahel bucks presented for slaughter in an abattoir.

Materials and methods

Sahel goats presented for slaughter at the Maiduguri Metropolitan abattoir were examined for abnormally small scrotal testes between March and April 2007 (dry season). The animals were identified by coat colour, weighed and aged. The age was estimated by observing the dentition of the animals (13). The weight measurements were taken using a weighing machine (HANA, China) calibrated in kilograms.

All the apparently small-sized testes, along with full-sized testes from 20 randomly selected mature bucks of comparable age and weight, were collected and weighed with a triple beam weighing balance (OHAUS, USA). The gross morphometry of the testes was estimated with a ruled measuring tape to obtain the testicular peripheral longitudinal lengths and mid-circumferences. The testes and epididymis were sliced and fixed in 10% buffered formalin. The fixed tissues were processed, embedded in paraffin wax, cut, and stained with haematoxylin and eosin (14).

The data were summarised as means \pm standard deviations and comparison of means was carried out by ANOVA with Tukey post-test and prevalence rates were compared as proportions by 2-sided Fisher's exact test using computer software (GraphPad Instat, 1993 version, www.graphpadinstat.com).

Results

Among the 1608 bucks examined within the study period, 1020 (63.4%) had plain coat colours, 563 (35.0%) had double coat colours, and 25 (1.6%) had multiple coat colours (Table 1). The majority of the bucks (42.6%) had plain white coat colour, whereas 23.1% had black-white coat colours. Most of the bucks (91.2%) were >1.5-3.0 years of age with mean weights of 15.6-25.7 kg (Table 2). The least number of bucks (0.3%), in >3.5-4.0 years age group, had the maximum mean body weights of 28.0-30.0 kg. The body weights of the bucks significantly ($P < 0.05$) increased with increasing age (Table 2), with body weights positively correlated with age ($r = 0.98$, $P < 0.01$).

Twenty-two (1.4%) out of the 1608 bucks had bilateral small-sized hypoplastic scrotal testes (Table 3). They were aged 1.9 ± 0.3 years and weighed $20.6 \pm$

Table 1. Frequency distribution of goats of various coat colours.

Coat colour	Number of goats (%)
Black	121 (7.5)
White	685 (42.6)
Brown	142 (8.8)
Tan	45 (2.8)
Grey	27 (1.7)
Black-white	371 (23.1)
Brown-white	142 (8.8)
Brown-black	50 (1.6)
Multiple colour	50 (1.6)
Total	1608 (100)

Table 2. Buck body weights at various ages.

Age (year)	Number (%)	Body weight (kg)
1.0-1.5	88 (5.5)	12.3 \pm 1.9 ^a
>1.5-2.0	468 (29.1)	15.6 \pm 2.7 ^b
>2.0-2.5	728 (45.3)	21.7 \pm 3.1 ^c
>2.5-3.0	271 (16.8)	25.7 \pm 3.0 ^d
>3.0-3.5	48 (3.0)	28.0 \pm 2.2 ^e
>3.5-4.0	5 (0.3)	30.0 \pm 2.1 ^e
	1608 (100)	22.2 \pm 2.5

^{a,b,c,d,e} Mean \pm SD with different superscripts are significantly different ($P < 0.001$)

3.5 kg. Out of the 9 coat colours observed among the bucks, 6 of them were in goats with bilateral testicular hypoplasia. The condition was most common among the bucks with brown-black coat colours, followed by those with brown-white coat colours, and prevalence rates among these coat colours were significantly ($P < 0.05$) higher than the rate among black-white bucks. There were no cases among those that had tan, grey, or multiple colours.

The gross morphometric parameters of the full-sized normal and small-sized hypoplastic testes from mature bucks are summarised in Table 4. The parameters were comparable for right and left testes, indicating symmetry of the size parameters in normal and hypoplastic testes. The hypoplastic testes were smaller morphometrically by 6.8-7.4 times in weight, 1.9 times in longitudinal length, 2.1

Table 3. Coat colour-specific prevalence of bilateral testicular hypoplasia in Sahel bucks.

Coat colour	Number examined	Number with hypoplasia	Prevalence (%)
White	685	11	1.6
Black	121	1	0.8
Brown	142	2	1.4
Black-white	371	1	0.3
Brown-white	142	4	2.8
Brown-black	50	3	6.0
	1608	22	1.4

times in mid-circumference, and grossly appeared smaller in the scrotal sac (Figure 1) as well as when dissected from the scrotum where their surfaces were smooth (Figure 2). The epididymis of the hypoplastic testis was apparently reduced in size as the testis. The seminiferous tubules and caudal epididymides of the hypoplastic testes lacked evidence of any spermatogenesis and the seminiferous tubules had smooth basement membranes (Figure 3).

Discussion

This study has shown the pattern of culling in relation to the coat colours, ages, and body weights of the bucks. The majority (65.7%) of goats presented for slaughter were white and black-white ecotypes. A low percentage (3.3%) of the population attained optimal mature weight at slaughter. Most of the bucks (91.2%) were brought to the abattoir at >1.5-3.0 years of age with mean weights of 15.6-25.7 kg. Mohammed and Amin (15) reported that the mean mature weight of

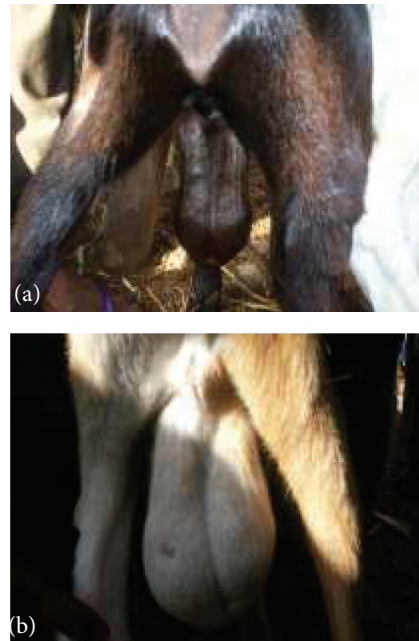

Figure 1. Posterior view of 2-year-old Sahel bucks with small-sized hypoplastic (a) and full-sized normal (b) testes in their scrotal sacs.

Table 4. Gross testicular morphometric parameters of normal and hypoplastic testes of Sahel bucks.

Testicular measurements	Normal testes from 20 bucks		Small hypoplastic testes from 22 bucks	
	Right side	Left side	Right side	Left side
Weight (g)	61.1 ± 14.0 ^a	57.1 ± 17.0 ^a	8.3 ± 4.2 ^b	8.3 ± 4.1 ^b
Longitudinal length (cm)	6.6 ± 0.7 ^a	6.5 ± 0.7 ^a	3.5 ± 1.3 ^b	3.6 ± 1.3 ^b
Mid-circumference (cm)	11.8 ± 1.1 ^a	11.7 ± 1.1 ^a	5.5 ± 1.8 ^b	5.5 ± 1.9 ^b

^{a,b} Mean ± SD with the different superscripts are significantly ($P < 0.05$) different.



Figure 2. Smaller testes of a buck with bilateral testicular hypoplasia (right) and full-sized testes (left) from a buck of comparable age.

adult plain white (Borno white) Sahel goats was 24.7 ± 5.3 kg. Kwari et al. (4) reported ages and weights of Sahel bucks at slaughter as 1.0-1.5 year and 11.5-24.5 kg, respectively. Mature adult weights of Sahel bucks were variously reported as 30-40 kg (3), 26.8-28.2 kg (16), and 25-37 kg (17).

Bilateral testicular hypoplasia had not been previously reported among the Sahel bucks in Nigeria. However, cases of testicular hypoplasia were reported in other parts of the world excluding Africa (18-23). Bilateral testicular hypoplasia was reported in a 1-year-old British Saanen male goat in which the abnormal testes were only slightly smaller than normal (18). Saanen goats with bilateral testicular hypoplasia exhibited male or female phenotype with sexual ambiguity (pseudohermatroditism) and homozygosity for polled gene and their bilaterally symmetric testes were half the normal size (19,20). A right unilateral testicular hypoplastic testis, half the normal size, was reported in a 1.5-year-old phenotypical male polled Saanen goat without intersexuality and homozygosity for polledness (22). Indian goats were reported to have 0.2% prevalence (2 out of 1000) of right unilateral testicular hypoplasia (21). An adult Nubian goat with male phenotype was reported to have testicular hypoplasia associated with mosaicism of the sex chromosomes (23).

The pathogenic basis for bilateral testicular hypoplasia in Sahel goats is unclear. Since the coat colour has slightly affected the prevalence and

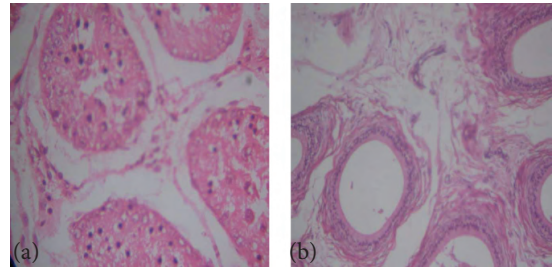


Figure 3. Photomicrograph of a hypoplastic testis (a) and its empty caudal epididymis (b), (H&E, $\times 100$).

coat colour is genetically determined, it is possible that the cause of the condition may have a genetic component. The testicular size of the hypoplastic testis was symmetrically reduced to half the normal or 7 times the normal when testicular length/mid-circumference or weight was considered, respectively, as were similarly reported in previous cases of hereditary testicular hypoplasia (19,20). The reduction in testicular size was also visually obvious from gross examination and farmers would be capable of diagnosing such cases in order to cull them from breeding programmes and avoid reproductive inefficiency.

Sponenberg et al. (22) suggested that some reported cases of testicular hypoplasia might appear as testicular degeneration. It is noteworthy that hypoplasia may elicit degenerative changes because of cellular dysfunctions arising from dysgenesis. If a testis has attained the mature size before a subsequent reduction in size as a result of atrophy arising from degenerative changes, the epididymis usually approximates the size of normal mature size and the testicular surface may be distorted (24). Thus, the reduction in size of the epididymis in testicular hypoplasia differentiates it from atrophy due to testicular degeneration. Moreover, severe degeneration of the seminiferous tubule in the full-sized testis leads to wrinkling of the basement membrane compared to smooth arrangement of the membrane during hypoplasia (12,24) observed in the reported cases. The hypoplastic testes of the Sahel bucks showed no evidence of spermatogenesis and the epididymides contained no spermatozoa even when they were aged more than 1 year. The bucks were reproductively dysfunctional judging from the fact that spermatogenesis was reported in the

normal bucks from 3 months of age, with sperm cell concentration in semen reaching 3.22×10^9 per mL at 1 year old (25).

In conclusion, occurrence of bilateral testicular hypoplasia among the characterised population of Sahel bucks in this report suggested the existence of unknown factors capable of contributing to reduced male reproductive efficiency in Nigeria.

References

1. Devendra, C., Mcleroy G.B.: Goat and Sheep Production in the Tropics. Intermediate Agric Series Longmans, London. 1982; 1-27.
2. Bourn, D., Wint, W., Blench, R., Woolley, E.: Nigerian livestock resources survey. *Wld. Anim. Rev.*, 1994; 78: 49-58.
3. Gall C.: Goat Breeds of the World. Margraf Verlag, Germany. 1996; 47-69.
4. Kwari, H.D., Sivachelvan, M.N., Chibuzo, G.A.: Characterization of Sahel goat in Borno state, Nigeria, for certain qualitative traits. *Nig. J. Exptl. Appl. Biol.*, 2004; 5: 151-154.
5. Alade, N.K., Adamu, S.B., Muhammed, I.D.: Breed and environmental effects on maturity of goats in semi-arid region of Nigeria. Proceedings of the 11th Annual Conference of Animal Science Association of Nigeria, September 18-21, 2006, IAR&T, Ibadan, Nigeria. 2006.
6. Raji, A.O., Igwebiuke, J.U., Aliyu, J.: Testicular biometry and relationship with body weight of indigenous goats in a semi arid region of Nigeria. *ARPN J. Agric. Biol. Sci.*, 2008; 3: 6-9.
7. Alamquist, J.O., Amann, R.P.: Reproductive capacity of dairy bulls II. Gonadal and extragonadal sperm reserves as determined by direct counts and depletion trials, dimensions and weight of genitalia. *J. Dairy Sci.*, 1961; 44: 1668-1678.
8. Lino, B.F.: The output of spermatozoa in rams. II. Relationship to scrotal circumference, testis weight, and the number of spermatozoa in different parts of the urogenital tract. *Aust. J. Biol. Sci.*, 1972; 25: 359.
9. Coulter, G.H., Foote, R.H.: Relationship of body weight to testicular size and consistency in growing Holstein bulls. *J. Anim. Sci.*, 1976; 44: 1076-1079.
10. Berndston, W.E., Thompson, T.L.: Changing relationships between testis size, Sertoli cell number and spermatogenesis in Sprague-Dawley rats. *J. Androl.*, 1990; 11: 429-435.
11. Blottner, S., Roelants, H., Wagener, A., Wenzel U.D.: Testicular mitosis, meiosis and apoptosis in mink (*Mustela vison*) during breeding and non breeding seasons. *Anim. Reprod. Sci.*, 1999; 57: 237-249.
12. Acland, H.M.: Male reproductive system. In: Carlton, W.W. and McGavin, M.D. ed. *Thompson's Special Veterinary Pathology*, 2nd edn. Mosby, Missouri, 1995; 544-560.
13. Chibuzo, G.A., Sivachelvan, M.N.: Ruminant Dissection Guide: A Regional Approach in the Goat, Faculty of Veterinary Medicine Occasional Publication No. 1, University of Maiduguri, Maiduguri, Nigeria 1994; 49-50.
14. Drury, R.A.B., Wallington E.A.: *Carleton's Histological Techniques*, 4th Edn. Oxford University Press, London. 1976; 21-71.
15. Mohammed, I.D., Amin, J.D.: 1996. Estimating body weight from morphometric measurements of Sahel (Borno White) goats. *Small Rumin. Res.*, 1996; 24: 1-5.
16. Dumas R.: Contribution a l'etude des petits ruminants du Tschad. *Rev. Elev. Med. Vet. Pays Trop.*, 1980; 33: 215-233.
17. Ngere, L.O., Adu, I.F., Okubanjo, I.O.: The indigenous goats of Nigeria. In: *Animal Genetic Resources Information No. 3*, 1-9, UNEP/FAO, Rome. 1984.
18. Rollinson, D.H.L.: A case of testicular hypoplasia in the goat. *Vet. Rec.*, 1950; 62: 303-304.
19. Soller, M., Laor, M., Barnea, R., Weiss, Y., Ayalon, N.: Polledness and infertility in male Saanen goats. *J. Hered.*, 1963; 54: 237-240.
20. Soller, M., Pageh, B., Wysoki, M., Ayalon, N.: Cytogenetics of Saanen goats showing abnormal development of the reproductive tract associated with the dominant gene of polledness. *Cytogenetics*, 1969; 8: 51-67.
21. Mathew, J., Raha, C.K.S.V.: 1978. Studies on testicular hypoplasia in goats. *Kerala J. Vet. Sci.*, 1978; 9: 24-30.
22. Sponengerg, D.P., Smith, M.C., Johnson, R.J.: Unilateral testicular hypoplasia in a goat. *Vet. Pathol.*, 1983; 20: 503-506.
23. Takebbayashi, S.S.G., Jorge, W.: Testicular hypoplasia in a horned goat with 61, XXY/60, XY karyotype. *Jpn J. Genet.*, 1986; 61: 177-181.
24. Foster, R.A.: Male reproductive system. In: McGavin M.D. and Zachary J.F. ed. *Pathologic Basis of Veterinary Disease*. 4th edn. Mosby Elsevier, Missouri. 2007; 1317-1348.
25. Maina V.A., Chaudhari, S.U.R., William, A.: Semen characteristics of the Brown Ecotype of Sahel goats in the semi-arid zone of Nigeria. *J. Appl. Sci.*, 2006; 6: 2329-2331.

Acknowledgements

This research was funded by the financial contributions of the authors. The histopathological slides were prepared by Alhaji Bukar Musa, FIMLS, Department of Histopathology, College of Medical Sciences, University of Maiduguri, Maiduguri. Photomicrographs were taken with the assistance of Dr Y. Abba.