

1-1-2011

Congenital secundum atrial septal defect and membranous ventricular septal defect in a newborn Holstein-Friesian calf

AYŞE HALIGÜR

MEHMET HALIGÜR

ÖZLEM ÖZMEN

Follow this and additional works at: <https://journals.tubitak.gov.tr/veterinary>



Part of the [Animal Sciences Commons](#), and the [Veterinary Medicine Commons](#)

Recommended Citation

HALIGÜR, AYŞE; HALIGÜR, MEHMET; and ÖZMEN, ÖZLEM (2011) "Congenital secundum atrial septal defect and membranous ventricular septal defect in a newborn Holstein-Friesian calf," *Turkish Journal of Veterinary & Animal Sciences*: Vol. 35: No. 5, Article 12. <https://doi.org/10.3906/vet-0907-121>
Available at: <https://journals.tubitak.gov.tr/veterinary/vol35/iss5/12>

This Article is brought to you for free and open access by TÜBİTAK Academic Journals. It has been accepted for inclusion in Turkish Journal of Veterinary & Animal Sciences by an authorized editor of TÜBİTAK Academic Journals. For more information, please contact academic.publications@tubitak.gov.tr.

Congenital secundum atrial septal defect and membranous ventricular septal defect in a newborn Holstein-Friesian calf

Ayşe HALIGÜR^{1*}, Mehmet HALIGÜR², Özlem ÖZMEN²

¹Department of Anatomy, Faculty of Veterinary Medicine, Mehmet Akif Ersoy University, Burdur - TURKEY

²Department of Pathology, Faculty of Veterinary Medicine, Mehmet Akif Ersoy University, Burdur - TURKEY

Received: 23.07.2009

Abstract: Congenital secundum atrial septal defect (ASD) and membranous ventricular septal defect (VSD) were diagnosed in a 1-day-old Holstein-Friesian calf necropsied in the Department of Pathology of Mehmet Akif Ersoy University. The secundum atrial septal defect was 32.9 × 23.1 mm in width and was elliptical. The membranous ventricular septal defect was 25.3 × 18.5 mm in width and was round to oval in shape. Both atrial and ventricular septal defects were stained with hematoxylin-eosin and Van Gieson's stain. Histopathological examination showed that the defects mainly consisted of numerous muscle cells and, in some areas, dense fibrous connective tissue.

Key words: Atrial septal defect, ventricular septal defect, calf, anatomy, pathology

Yeni doğmuş bir Holstein-Friesian buzağısında konjenital secundum atrial septal defekt ve membranöz ventriküler septal defekt

Özet: Patoloji anabilim dalında nekropsisi yapılan, Holstein-Friesian ırkı, 1 günlük bir buzağıda konjenital sekundum atrial septal defekt ve membranöz ventriküler septal defekt tanımlandı. Sekundum atrial septal defekt elips şeklinde, 32,9 × 23,1 mm idi. Membranöz ventriküler septal defekt oval şeklinde, 25,3 × 18,5 mm idi. Histopatolojik olarak hem atrial hem de ventriküler septal defekt hematoksilin-eozin ve Van Gieson metodu ile boyandı. Histopatolojik incelemede defektlerin yoğun fibröz doku ile bazı bölgelerde kas hücrelerinden oluştuğu saptandı.

Anahtar sözcükler: Atrial septal defekt, ventriküler septal defekt, buzağı, anatomi, patoloji

Introduction

In cattle, congenital cardiac malformations are rare (1). The frequency of cardiac malformation is 2.7% in calves (2), but ventricular septal defect (VSD) is one of the most important cardiac abnormalities (1,3). Membranous VSD is one of the most common forms of congenital heart malformation in both humans and animals (4). In some VSD cases, the

failure of the atrioventricular and bulbus arteriosus partitions of the heart muscle to completely fuse results in a ventricular septal defect. During normal embryogenesis, fusion with the membranous portion of the septum growing downward from the bulbus arteriosus is observed. Failure of this fusion results in a ventricular septal defect (5). Atrial septal defect (ASD) has been infrequently reported in dogs and

* E-mail: ahaligur@mehmetakif.edu.tr

cats (6). It can be characterized as having 3 forms: ostium primum ASD, ostium secundum ASD, and sinus venosus ASD (5).

This paper is the first report describing the presence of both congenital secundum atrial septal and membranous ventricular septal defects in the heart of a Holstein-Friesian calf.

Case history

A male Holstein-Friesian calf found dead by the owner of a private cattle farm was submitted to the Department of Pathology of Mehmet Akif Ersoy University for diagnosis of the cause of death. It was stated that the calf had survived for only 2 h. No pathological findings were observed upon general examination. In necropsy, a secundum atrial and a membranous ventricular septal defect were detected during the examination of the heart. Tissue samples were collected for histopathological examination. Samples were fixed in 10% neutral buffered formalin and routinely processed for histopathology. Tissues embedded in paraffin were sectioned at 5 μ m and were stained using the hematoxylin-eosin (HE) and Van Gieson methods for fibrous tissue.

Results and discussion

The owner stated that no complications had been seen during the birth and the calf had been delivered without help. The mother cow had not been suffering

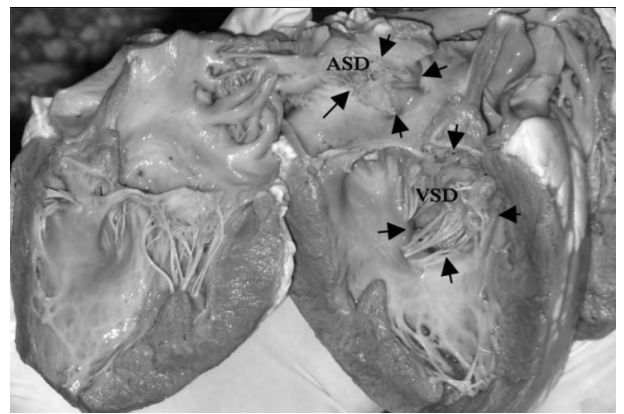


Figure 1. The heart of a Holstein-Friesian calf, with the secundum atrial septal defect (ASD) and the membranous ventricular septal defect (VSD) viewed from the left surface of the septum.

from any disease. This was her first pregnancy and normal procedures were observed during the pregnancy. However, the calf could not stand up and had respiratory distress. Marked cyanosis was observed before death. The calf was born alive but died 2 h after birth.

During necropsy, the heart was seen to have a normal shape and localization when the pectoral cavity was opened. Vascularization of the heart was normal. During the dissection and examination of the heart, 2 different defects were observed. One of these was localized on the interatrial septal wall (Figures 1, 2A, and 2B) and the other was localized

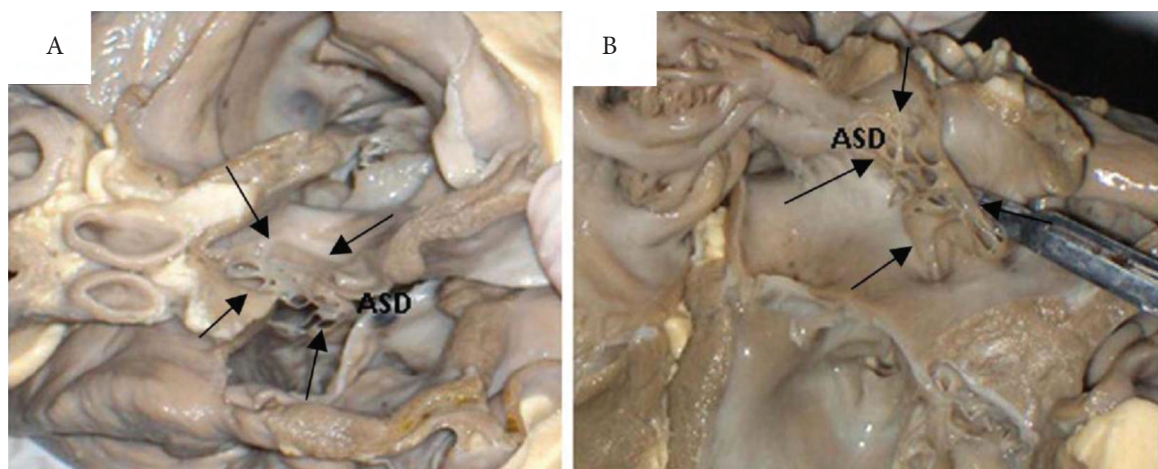


Figure 2. A) The heart of a Holstein-Friesian calf, with the secundum atrial septal defect (ASD) viewed from the dorsal aspect; B) the secundum atrial septal defect (ASD) viewed from the left surface of the septum.

on the interventricular septal wall (Figures 1, 2A, and 2B).

The persistent ostium secundum ASD was elliptical and had resulted from incomplete closure of the fossa ovalis of the septum interatriale. The defect was measured as 18.5×25.3 mm and was covered with a cuspid-like structure that measured 12.8 mm in length.

The ventricular septal defect, present in the left atrioventricular orifice, was seen as a membranous structure with oval shape. The VSD measured 32.9×23.1 mm, dorsal to ventral. A large portion of the VSD was closed by the chordae tendineae of the septal cusp in the left ventricle (Figure 1). Both the ASD and the VSD allowed the shunting of blood between the left and right cavities. The aortic orifice and the opening of the pulmonary trunk were normal.

In addition to these findings, some areas exhibited small, reddish-to-black lesions, between 0.9 to 4.2 mm in width and 1.0 to 5.9 mm in length. Lesions were seen in the radix and center of the anterior cusp and in the center of the posterior cusp in the left ventricle. Similar lesions were detected in the left ventricle on the tendinous cord and near the radix of the septal cusp.

Histopathological examination of the HE-stained slides revealed that the defects consisted of chiefly fibrous tissue and scanty muscle fibers, which had originated from the myocardium (Figure 3). The

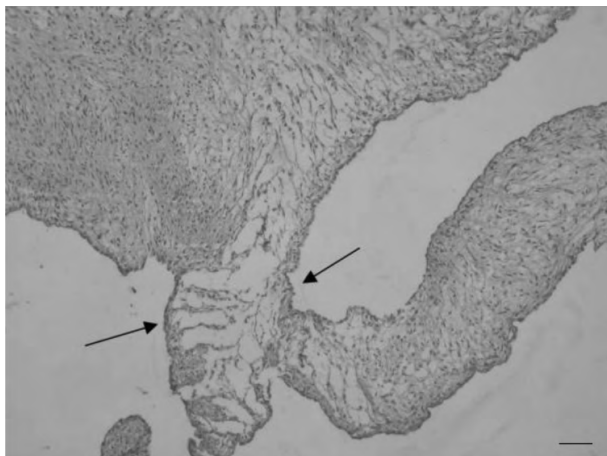


Figure 3. The histopathological appearance of the VSD defective area of the heart, showing endocardial cells (arrows), HE stain, bar = 100 μ m.

muscle fibers did not have the normal striated myocardial cell appearance and there were no intercalated disk (end-to-end joining of myocytes) or lateral junction (side-to-side connection) formations as occur in a normal myocardium. The nuclei of the myocytes were elongated and centrally located. There were no Purkinje fibers in the defective areas. Endocardial elements covered the defect. Hemorrhages were seen in the reddish areas. The Van Gieson-stained slides supported the dense fibrous structure of the defects (Figure 4). Marked collagen fibers were more prominent in these slides.

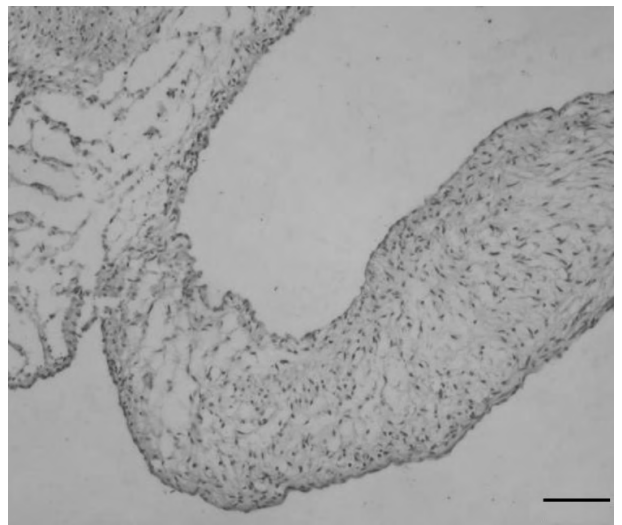


Figure 4. The microscopic appearance of the VSD, Van Gieson's stain, bar = 200 μ m.

There are 3 major arteriovenous communications in the development of the heart. These communications are localized between the atria, the ventricles, and the great vessels (5). Defects such as patent ductus arteriosus, ASD, and VSD constitute failures of closure. Failure of closure may itself cause several possible defects. Insufficient closure of the interventricular septum is termed VSD (1-3,5). It is usually seen singly and may be small and without functional significance, or it can be quite large. A systolic murmur is usually recognizable due to the higher pressure in the left ventricle. Severe cardiac dysfunction is seen in large defects. Thus, left heart failure or chronic heart failure causes death. In domestic animals and humans, VSD is one of the

most common cardiac malformations (1,3,5,7-9). VSD constitutes over 20% of all congenital cardiac disease and is generally perimembranous, involving the membranous septum and the adjacent area of the muscular septum (5,10-15). In this study, VSD was seen as membranous and the localization of the defect was in the dorsal portion of the septum. Therefore, it was diagnosed as a membranous ventricular septal defect. The heart lesion was identified as a congenital malformation of the heart, because it was stated that the calf had survived for only 2 h.

ASD can take 3 forms: ostium primum ASD, ostium secundum ASD, and sinus venosus ASD. These malformations are formed during

embryogenesis. Failure of closure of the interatrial communication is termed ASD (1-3,5). This pathologic defect causes excessive flow from the left to the right atrium, impacts the overloading of the right ventricle, and results in elevated central venous pressure. Cyanosis can be seen due to pulmonary hypertension stemming from flow through the defect in some cases (1-3,5,7,9). Our case revealed that the defects in the atrium and ventricle were secundum ASD and membranous VSD, respectively. The animal survived for 2 h after birth and then died. Thus, these malformations were evaluated as congenital and as having formed during embryogenesis. This case is the first report of both atrial and ventricular septal defects occurring together in a newborn calf.

References

1. Van Nie, C.J.: Congenital malformations of the heart in cattle and swine. *Acta Morphol. Neerl. Scand.*, 1966; 6: 387-393.
2. Leipold, H.W., Dennis, S.M., Huston, K.: Congenital defects in cattle: nature, cause and effect. *Adv. Vet. Sci. Comp. Med.*, 1972; 16: 103-150.
3. Ohwada, K., Murakami, T.: Morphologies of 469 cases of congenital heart diseases in cattle. *J. Jap. Vet. Med. Assoc.*, 2000; 53: 205-209.
4. Detweiler, D.K.: Genetic aspects of cardiovascular diseases in animals. *Circulation*, 1964; 30: 114-127.
5. Jones, T.C., Hunt, R.D., King, N.W.: Cardiovascular system. In: Jones, T.C., Hunt, R.D., King, N.W., Eds. *Veterinary Pathology*, 6th ed. Lippincott Williams & Wilkins, Maryland, USA. 1997; 976-977.
6. Özyiğit, G., Arıcan, İ., Özyiğit, M.Ö., Yılmaz, B.: Secundum atrial septal defect in a one-year-old Kangal dog. *Turk. J. Vet. Anim. Sci.*, 2006; 30: 343-345.
7. West, H.J.: Congenital anomalies of the bovine heart. *Br. Vet. J.*, 1988; 144: 123-130.
8. Fischer, E.W., Pirie, H.M.: Cardiovascular lesions in cattle. *Ann. N.Y. Acad. Sci.*, 1965; 127: 606-622.
9. Gopal, T., Leipold, H.W., Dennis, S.M.: Congenital cardiac defects in calves. *Am. J. Vet. Res.*, 1986; 47: 1120-1121.
10. Rigby, M.L., Redington, N.: Primary transcatheter closure of perimembranous ventricular septal defect. *Br. Heart J.*, 1994; 72: 368-371.
11. Vogel, M., Rigby, M.L., Shore, D.: Perforation of the aortic valve cusp: complication of ventricular septal defect closure with a modified Rashkind umbrella. *Pediatr. Cardiol.*, 1996; 17: 416-418.
12. Kalra, G.S., Verma, P.K., Dhall, A.: Transcatheter device closure of perimembranous septal defects: immediate results and intermediate-term follow-up. *Am. Heart J.*, 1999; 138:339-344.
13. Sideris, E.B., Walsh, K.P., Haddad, J.L.: Occlusion of congenital ventricular septal defects by the buttoned device. *Heart*, 1997; 77: 276-279.
14. Gu, X., Han, Y.M., Titus, J.L.: Transcatheter closure of membranous ventricular septal defects with a nitinol prosthesis in a natural swine model. *Cathet. Cardiovasc. Interv.*, 2000; 50: 502-509.
15. Buczinski, S., Fecteau, G., DiFruscia, R.: Ventricular septal defects in cattle: a retrospective study of 25 cases. *Can. Vet. J.*, 2006; 47: 246-252.