

1-1-2012

Unusual anal atresia in a lamb

SIAVASH AHMADI NOORBAKHS

Follow this and additional works at: <https://journals.tubitak.gov.tr/veterinary>



Part of the [Animal Sciences Commons](#), and the [Veterinary Medicine Commons](#)

Recommended Citation

NOORBAKHS, SIAVASH AHMADI (2012) "Unusual anal atresia in a lamb," *Turkish Journal of Veterinary & Animal Sciences*: Vol. 36: No. 1, Article 12. <https://doi.org/10.3906/vet-1012-661>

Available at: <https://journals.tubitak.gov.tr/veterinary/vol36/iss1/12>

This Article is brought to you for free and open access by TÜBİTAK Academic Journals. It has been accepted for inclusion in Turkish Journal of Veterinary & Animal Sciences by an authorized editor of TÜBİTAK Academic Journals. For more information, please contact academic.publications@tubitak.gov.tr.

Unusual anal atresia in a lamb

Siavash AHMADI NOORBAKHSH*

Department of Surgery, Faculty of Veterinary Medicine, University of Urmia, Urmia - IRAN

Received: 18.01.2011

Abstract: The first report of an unusual anal atresia with growth of ectodermal organs (wool and skin) in the shape of the intestine inside the body is provided here. During reconstructive surgery, a rectum-like structure was noted, in which wool strands grew densely. A hypothetical mechanism by which this structure formed is presented on the basis of local alterations in fetal tissue proliferation and rate of development.

Key words: Atresia ani, lamb, congenital disorder, rectum, ectoderm

Introduction

Anal atresia (AA) may be caused by genetic disorders (chromosomes or transgenes), environmental factors (management techniques, infections, toxins, or fertilization method), or a combination of both (1-4); however, its exact etiology is not fully understood (1,5). AA is usually associated with additional anomalies in other organs (3,5). During normal embryogenesis, each cell of a vertebrate body is derived from 1 of the 3 fundamental cellular layers: the ectoderm, mesoderm, and endoderm (6). In particular, the epidermis, the external body coating, and a few millimeters of the distal part of the anal canal are derived from the ectoderm. The endoderm forms nearly the whole of the epithelial lining of the digestive tract, with 2 exceptions: the distal part of the anal canal and parts of the mouth and pharynx, which develop from the ectoderm. The mesoderm contributes to the development of the intestinal wall, blood, and blood vessels. During early fetal stages, a thin "anal membrane" will separate the ectodermal anal canal from the endodermal intestine

(6). Normally, this membrane ruptures, and the 2 parts unify before birth. Failure of this membrane to rupture during fetal development will cause AA (4,6). Failure of intestinal canalization, failure in proctodeum invagination, failure in development of the dorsal part of the cloacal plate, or disruption of the anal blood supply can also cause AA (1). For more information on this process, please refer to the work of Noden and De Lahunta (6).

Case history

A 2-day-old male domestic lamb, weighing 2.8 kg, with an imperforate anus was delivered naturally by a 4-year-old ewe that had mated with a domestic ram. The lamb's abdomen was distended and painful. On auscultation, a gurgling sound was heard in the right ventral abdominal region. There was a skin remnant of an imperforate anus. The heart rate was 140 beats/min, the respiratory rate was 52 breaths/min, and the lamb had pink mucous membranes with a slightly elevated capillary refill time of approximately 3 s.

* E-mail: s.noorb@gmail.com

Radiographs showed a large-bore gas-filled loop of the descending colon terminating inside the pelvic cavity; this loop was extended toward the perineum with a semiopaque density.

Reconstructive surgery was done according to the literature methods (7). Unexpectedly, a dense mass of wool was observed when a stab incision was made into the rectum-like organ (Figure 1). The wool appeared to be the same as that of the lamb's coat. The wool was clear, shiny, white, and dry and was grown from the underlying tissue, similar to the fleece. The rectum-like structure (RLS) had a cylindrical shape. A firm membranous barrier was observed approximately 5 cm proximal to the opening by instrumental manipulation. The RLS had a constant diameter of approximately 1.5 cm throughout its length.

The owner requested that the lamb be kept alive. Therefore, a salvage right-midflank diverting loop colostomy was performed according to the textbook methods (7).

During laparotomy, the descending colon was found to be severely distended with gaseous contents. It was separated from the RLS (the narrower tube) by the aforementioned firm membranous barrier. Figure 2 shows the left side of the great mesentery. The growth of the ascending spiral colon was incomplete, and there were no centripetal or centrifugal coils (gyri) or central flexure. The hypoplastic ascending colon was filled with liquid and little gaseous content. The jejunum was uncharacteristically filled with moderate amounts of ingesta. Branches of the cranial mesenteric artery, including the arcade vessels and

vasa recta that supply the jejunum and hypoplastic ascending colon, were severely dilated and had an abnormal distribution pattern in the mesentery, with fewer branches and anastomoses than normal. No fistula was connected to the RLS. No other observable abnormality was identified in the abdominal cavity. Anesthetic recovery was uneventful. Unfortunately, the lamb died approximately 6 h after the operation.

Results and discussion

With regard to this anomaly, because there was no detailed information on the pregnancy or the fetal development of the lamb, the cause could not be determined. Despite this limitation, I attempted to establish the most likely and novel etiology on the basis of embryological development concepts.

In this case, I was unsure of whether it should have been designated a rectal atresia or rectal agenesis, because signs of both were observed. Although the subject did not develop an ordinary rectum, a tubal structure that had a normal rectal diameter and length was located in the exact anatomical location of the rectum (inside the pelvic cavity from the pelvic inlet to the anal canal), connected to the descending colon proximally via a membranous barrier and located close to the perineal skin distally, as in the case of a simple AA. Thus, from its macroscopic similarities to a normal rectum, the term "rectal dysplasia" is more precise than "rectal agenesis." However, atresia is the absence or closure of a natural opening or lumen (5), and the presence of a thin endodermal fibrous cord between the descending colon and anal canal can also

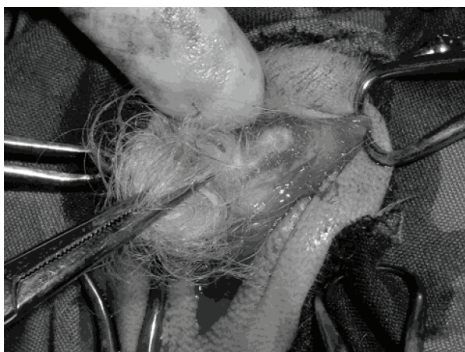


Figure 1. Dense mass of wool, developed into a rectum-like structure, in a newborn lamb with anal atresia.

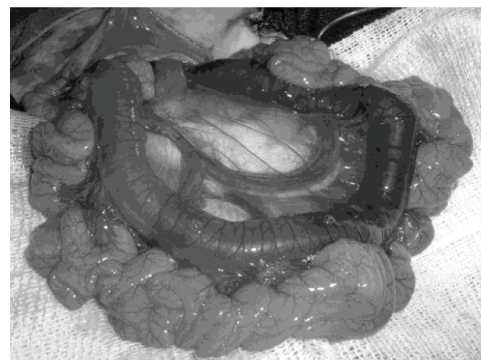


Figure 2. Enormously dilated vessels, hypoplasia of the ascending spiral colon, colon distension, and jejunal filling at the left side of the great mesentery.

be termed “atresia” (8). “Rectal atresia” is a condition involving the rectum or its remnants as “endodermal organs.” In this study, the RLS was an ectodermally derived structure, and to define it as a “rectal atresia” appears to be incorrect.

Rectal surgery is best studied in small animals. However, techniques can be generalized to large animals with few modifications (7,9). The rectum may be approached via a ventral (for lesions involving the colorectal junction and throughout the rectum), dorsal (for lesions at the caudal and middle rectum, except those in the anal canal and cranial rectum), lateral (for limited exposure of one side of the rectum), rectal pull-through (for distal colonic and midrectal lesions), Swenson’s pull-through (for extensive lesions throughout the rectum and distal colon), or anal (for lesions at the caudal rectum and anal canal) approach. For a complete explanation of these techniques, please refer to the work of Fossum et al. (9).

In the present case, since the whole length of the rectum was affected, only the ventral or rectal pull-through approaches were feasible. The ventral approach requires pubic symphysiotomy or pubic osteotomy (9). Both procedures are severely traumatic and out of the tolerance of a debilitated 2-day-old lamb. For the rectal pull-through approach, it is necessary to avert the rectum through the anus (9). Several attempts to exteriorize the rectum failed. Therefore, these approaches were dismissed and euthanasia was the only way to remove the affected organ for a profound investigation.

The external coating of the skin is an ectodermal derivative and is unrelated to where it developed (10); therefore, the aforementioned RLS could not be an endodermal or solely mesodermal organ. The border that develops between the ectodermal anal canal and the endodermal intestine during embryogenesis is the anal membrane (10). Thus, the separating membrane of the tubal structure between the endodermal descending colon and ectodermal RLS was merely a persistent, overinvaginated anal membrane. The blind end of the RLS was close to the perineal skin, and, likely, the ectodermal tissue of the RLS translocated from the surface ectoderm of the perineal skin. During invagination, the ectodermal anal canal appeared to have been penetrated inside the body, developing a wool-coated tubal structure during embryogenesis

(Figure 3). The absence of amniotic fluids inside the RLS might implicate rapid closure of the distal part of the RLS with surface ectodermal tissue during the early development of the anomaly.

Furthermore, elongation of the ectodermally derived tubal structure far into the pelvic cavity was associated with global hypoplasia of the large intestines. Incomplete formation of the ascending spiral colon has been proposed to result from a fundamental disorder in endodermal tissue formation or the lack of a natural distribution of vessels in this area (6). Vascular disorders have been proposed to be the cause of intestinal atresia in a calf (1).

Therefore, I propose 2 novel mechanisms for the presence of the RLS: 1) an increased proliferation rate of the anal regional ectoderm, associated with the outer pressure of the amniotic fluid, caused the “proctodeum” to penetrate into the pelvic cavity; or 2) the decreased proliferation rate of the endodermal intestine was incompatible with fetal elongation, and it dragged tissues that were attached to it (the ectodermal anal canal) inside the body. In either mechanism, it appears that shortly after the invagination, the base of the proctodeum was closed by unification of the surface ectoderm, and the incarcerated ectodermal tissue continued to grow and replace the rectum (Figure 3).

In conclusion, despite the lack of a definitive etiology, the present case showed that an ectopic tissue developed in an unusual shape and position while retaining its original macroscopic characters; this finding might have implications for tissue engineering studies.

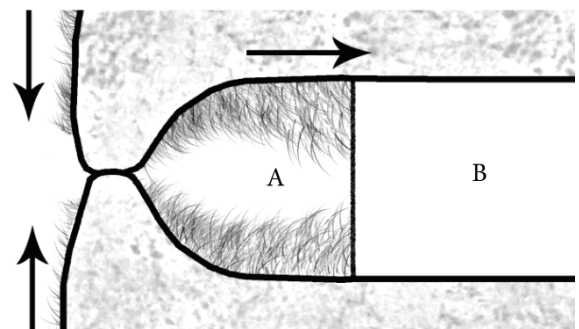


Figure 3. An invaginated space lined by the surface ectoderm may have been entrapped (A) and continued to proximal growth, forming a rectum-like structure connected to the descending colon (B) via a membranous barrier.

References

1. Newman, S.J., Bailey, T.L., Jones, J.C., DiGrassie, W.A., Whittier, W.D.: Multiple congenital anomalies in a calf. *J. Vet. Diagn. Invest.*, 1999; 11: 368-371.
2. Bai, Y., Chen, H., Yuan, Z.W., Wang, W.: Normal and abnormal embryonic development of the anorectum in rats. *J. Pediatr. Surg.*, 2004; 39: 587-590.
3. Ghanem, M., Yoshida, C., Isobe, N., Nakao, T., Yamashiro, H., Kubota, H., Miyake, Y., Nakada, K.: Atresia ani with diphallus and separate scrota in a calf: a case report. *Theriogenology*, 2004; 61: 1205-1213.
4. Cassini, P., Montironi, A., Botti, S., Hori, T., Okhawa, H., Stella, A., Andersson, L., Giuffra, E.: Genetic analysis of anal atresia in pigs: evidence for segregation at two main loci. *Mamm. Genome*, 2005; 16: 164-170.
5. Ghanem, M.E., Yoshida, C., Nishibori, M., Nakao, T., Yamashiro, H.: A case of freemartin with *atresia recti* and *ani* in Japanese Black calf. *Anim. Reprod. Sci.*, 2005; 85: 193-199.
6. Noden, D.M., De Lahunta, A.: *The Embryology of Domestic Animals: Developmental Mechanisms and Malformations*. Williams & Wilkins, Baltimore. 1985.
7. Oehme, F.W.: *Textbook of Large Animal Surgery*. Williams & Wilkins, Baltimore. 1988; 461-468, 492.
8. Magnus, R.V.: Rectal atresia as distinguished from rectal agenesis. *J. Pediatr. Surg.*, 1968; 3: 593-598.
9. Fossum, T.W., Hedlund, C.S., Johnson, A.L., Schulz, K.S., Seim, H.B., Willard, M.D., Bahr, A., Carroll, G.L.: *Small Animal Surgery*. 3rd edn., Elsevier, Boston. 2007; 480-489, 501-505.
10. Langman, J., Sadler, T.W.: *Langman's Medical Embryology*. 6th edn., Williams & Wilkins, London. 1990; 255-259, 268-269, 283-284.