

1-1-2017

The diagnostic accuracy of endobronchial ultrasound-guided transbronchial needle aspiration (EBUS-TBNA) in mediastinal tuberculous lymphadenitis

ONUR FEVZİ ERER

SERHAT EROL

CEYDA ANAR

CAN BİÇMEN

ZEKİYE AYDOĞDU

See next page for additional authors

Follow this and additional works at: <https://journals.tubitak.gov.tr/medical>

 Part of the [Medical Sciences Commons](#)

Recommended Citation

ERER, ONUR FEVZİ; EROL, SERHAT; ANAR, CEYDA; BİÇMEN, CAN; AYDOĞDU, ZEKİYE; and ÖZKAN, SERİR (2017) "The diagnostic accuracy of endobronchial ultrasound-guided transbronchial needle aspiration (EBUS-TBNA) in mediastinal tuberculous lymphadenitis," *Turkish Journal of Medical Sciences*: Vol. 47: No. 6, Article 31. <https://doi.org/10.3906/sag-1606-110>

Available at: <https://journals.tubitak.gov.tr/medical/vol47/iss6/31>

This Article is brought to you for free and open access by TÜBİTAK Academic Journals. It has been accepted for inclusion in Turkish Journal of Medical Sciences by an authorized editor of TÜBİTAK Academic Journals. For more information, please contact academic.publications@tubitak.gov.tr.

The diagnostic accuracy of endobronchial ultrasound-guided transbronchial needle aspiration (EBUS-TBNA) in mediastinal tuberculous lymphadenitis

Authors

ONUR FEVZİ ERER, SERHAT EROL, CEYDA ANAR, CAN BİÇMEN, ZEKİYE AYDOĞDU, and SERİR ÖZKAN

The diagnostic accuracy of endobronchial ultrasound-guided transbronchial needle aspiration (EBUS-TBNA) in mediastinal tuberculous lymphadenitis

Onur Fevzi ERER¹, Serhat EROL^{2,*}, Ceyda ANAR¹, Can BİÇMEN³, Zekiye AYDOĞDU⁴, Serir AKTOĞU¹

¹Department of Chest Diseases, Dr. Suat Seren Chest Diseases and Thoracic Surgery Teaching and Research Hospital, İzmir, Turkey

²Department of Pulmonary Diseases, School of Medicine, Ankara University, Ankara, Turkey

³Department of Microbiology, Dr. Suat Seren Chest Diseases and Thoracic Surgery Teaching and Research Hospital, İzmir, Turkey

⁴Department of Pathology, Dr. Suat Seren Chest Diseases and Thoracic Surgery Teaching and Research Hospital, İzmir, Turkey

Received: 22.06.2016 • Accepted/Published Online: 03.10.2017 • Final Version: 19.12.2017

Background/aim: Mediastinal lymph nodes are the second most commonly affected lymph nodes in tuberculous lymphadenitis. It is often difficult to diagnose tuberculosis in patients with lymphadenopathy without parenchymal lesions. The aim of this study was to describe the diagnostic utility of endobronchial ultrasound-guided transbronchial needle aspiration (EBUS-TBNA) in patients with isolated mediastinal tuberculous lymphadenitis (MTLA).

Materials and methods: This study included 527 patients who had undergone EBUS-TBNA between December 2012 and December 2014. Patients with the final diagnosis of MTLA were evaluated. The sensitivity, specificity, positive predictive value (PPV), negative predictive value (NPV), and accuracy of EBUS-TBNA were calculated.

Results: The prevalence of MTLA in all patients who had undergone EBUS-TBNA for mediastinal lymphadenopathy of unknown etiology was 5.2% (28/527). EBUS-TBNA was diagnostic in 21/28 (75%) patients, and the remaining 7 patients required additional procedures for confirmation of diagnosis. Sensitivity, specificity, PPV, NPV, and accuracy of combined cytopathological and microbiological examinations of EBUS-TBNA in the diagnosis of MTLA were 87.5%, 98.5%, 91.4%, 98%, and 94.4%, respectively. There were no major complications.

Conclusion: EBUS-TBNA is a safe and effective procedure for the diagnosis of MTLA. When microbiological and cytopathological examinations of samples are combined, EBUS-TBNA demonstrates good diagnostic accuracy and NPV for the diagnosis of MTLA.

Key words: Lymphadenitis, tuberculosis, mediastinal diseases, endobronchial ultrasound

1. Introduction

Tuberculous lymphadenitis is the most common form of extrapulmonary tuberculosis (EPT) (1). The most commonly affected lymph nodes (LNs) are the cervical, followed by mediastinal, supraclavicular, and inguinal LNs (2). In the International Standards for Tuberculosis Care it is recommended that microbiological confirmation must be made, and diagnostic materials should be obtained for microbiological and histopathological evaluation for diagnosis of EPT (3). While it is relatively easy to obtain lymph node aspiration or excisional biopsy materials from the peripheral lymph nodes, like the cervical lymph node, obtaining material for mediastinal tuberculous lymphadenitis (MTLA) is difficult (4,5). Diagnosis maybe difficult in the absence of accompanying parenchymal involvement; the vast majority of such cases have negative

sputum smears and cultures. Radiological findings of an adenopathy do not confirm the diagnosis. Moreover, fungal infections or malignancy can also produce similar radiological abnormalities.

Mediastinoscopy has been successfully used for MTLA diagnosis for many years (6). However, compared to mediastinoscopy, endobronchial ultrasound-guided transbronchial needle aspiration (EBUS-TBNA) is minimally invasive, with lower morbidity and mortality rates, and can be performed as an outpatient procedure and under conscious sedation. Therefore, EBUS-TBNA has become the first-line procedure for evaluation of mediastinal LNs (7).

In this study, we aimed to describe the diagnostic utility of EBUS-TBNA in patients with isolated intrathoracic lymphadenopathy due to tuberculosis.

* Correspondence: drserol@yahoo.com

2. Materials and methods

2.1. Study design and case selection

We retrospectively evaluated our database for patients who underwent EBUS between December 2012 and December 2014. Over the study period, a total of 527 patients underwent EBUS-TBNA for the staging and diagnosis of primary lung cancer, extrapulmonary malignancy, MTLA, sarcoidosis, and a variety of clinical indications. Only patients with a final diagnosis of MTLA were included in the study.

2.2. The EBUS-TBNA procedure

All EBUS-TBNA procedures were performed by the same bronchoscopist. The EBUS-TBNA procedure was performed by an EBUS-guided TBNA bronchoscope (7.5 MHz, BF-UC160F; Olympus, Tokyo, Japan) under conscious sedation with intravenous midazolam. An examination of all mediastinal and hilar lymph node stations accessible by EBUS was performed prior to the TBNA procedure. Each target nodal station was punctured at least three times, and one or more tissue core specimens were obtained with a dedicated 22-gauge needle (NA-201SX-4022; Olympus). The aspirate was then blown onto a glass slide by pushing air using a 20-mL syringe. All patients provided informed consent before the endoscopic procedure. The study was approved by the institutional ethics committee.

2.3. Cytopathological examination

Some amount of aspirate was smeared onto glass slides, air-dried, fixed immediately with 95% alcohol, and stained with hematoxylin and eosin (H&E). The rest of the aspirate was placed into a mixture of formalin and alcohol in order to obtain a cell block for histological examination. A cell block was obtained for all patients. Rapid on-site cytological examination was not available.

2.4. Mycobacterial cultivation, identification, and molecular detection

Fine-needle aspiration biopsy specimens were suspended in 1 mL of Middlebrook 7H9 medium and vortexed. Mycobacterial cultivation was performed by the MGIT 960 system (BD Biosciences, Sparks, MD, USA) according to the recommendations of the manufacturer, as described elsewhere (8), and in Lowenstein-Jensen slants (Salubris AS, İstanbul, Turkey). An acid-fast smear preparation by fluorochrome and/or Kinyoun staining was also applied to each processed specimen. Differentiation of *M. tuberculosis* and nontuberculous mycobacteria was performed by conventional methods (9). Mycobacterial cultures were obtained in all patients.

Nucleic acid amplification tests (NAATs) were used as the method of detecting the presence of *M. tuberculosis* complex DNA directly from clinical specimens during the study period. The test was the BD ProbeTec ET

Mycobacterium tuberculosis Complex (DTB) (BD Biosciences) and it was performed and evaluated according to the recommendations of the manufacturer.

2.5. Final diagnoses of MTLA

Patients were considered to have a diagnosis of MTLA if there was high clinical and radiological suspicion with one or more of the following criteria:

- 1) At least one positive culture of sputum and/or TBNA specimens for *Mycobacterium tuberculosis*;
- 2) At least one acid-fast bacilli (AFB) test and/or NAAT positive for sputum and/or TBNA specimens;
- 3) Pathologic results showing granulomatous inflammation with necrosis or without necrosis, and clinicoradiological response to antituberculosis treatment.

The diagnosis of sarcoidosis was made based on the presence of consistent clinical and radiological presentation, demonstration of granulomas on EBUS with negative AFB and no growth of mycobacteria on culture, and clinical and radiological response after treatment with glucocorticoids or spontaneous remission. EBUS-TBNA results were considered malignant when the aspirated material contained malignant cells. A lymph node was accepted as anthracotic adenitis if the microscopic examination of a specimen revealed anthracotic pigments. In the presence of lymphocytes, macrophages, and immunoblasts and no presence of malignant cells, granulomatous inflammation, compact anthracotic pigment, and abundantly epithelia cells, cases were evaluated by the pathologists under the microscopic examination of aspiration and histological specimens; if they remained stable for at least 1 year the lymph node was accepted as reactive adenitis.

2.6. Statistical analysis

Statistical analyses were performed using SPSS 20 (IBM Corp., Armonk, NY, USA). Descriptive statistics were expressed as mean \pm standard deviation for continuous variables and as frequency (percentage) for categorical variables. The sensitivity and negative predictive value (NPV) of EBUS-TBNA were calculated.

3. Results

Between December 2012 and December 2014, a total of 527 patients underwent EBUS-TBNA; the final diagnosis was MTLA in 28 patients (Figure). There were 10 male and 18 female patients with a mean age of 53.4 ± 15.9 years. Sixty-eight LNs were sampled. Subcarinal (station 7) and right lower paratracheal (station 4R) were the most sampled LNs (Table 1). All cases were negative for HIV.

Twenty-one (75%) of patients with MTLA were diagnosed with EBUS-TBNA. In 15 of these patients, at least one of the NAATs, AFB smears, or cultures of EBUS-TBNA samples were positive for *M. tuberculosis*. PCR was positive in 4 (14.3%) patients, AFB in 4 (14.3%) patients, and culture in 13 (46.4%).

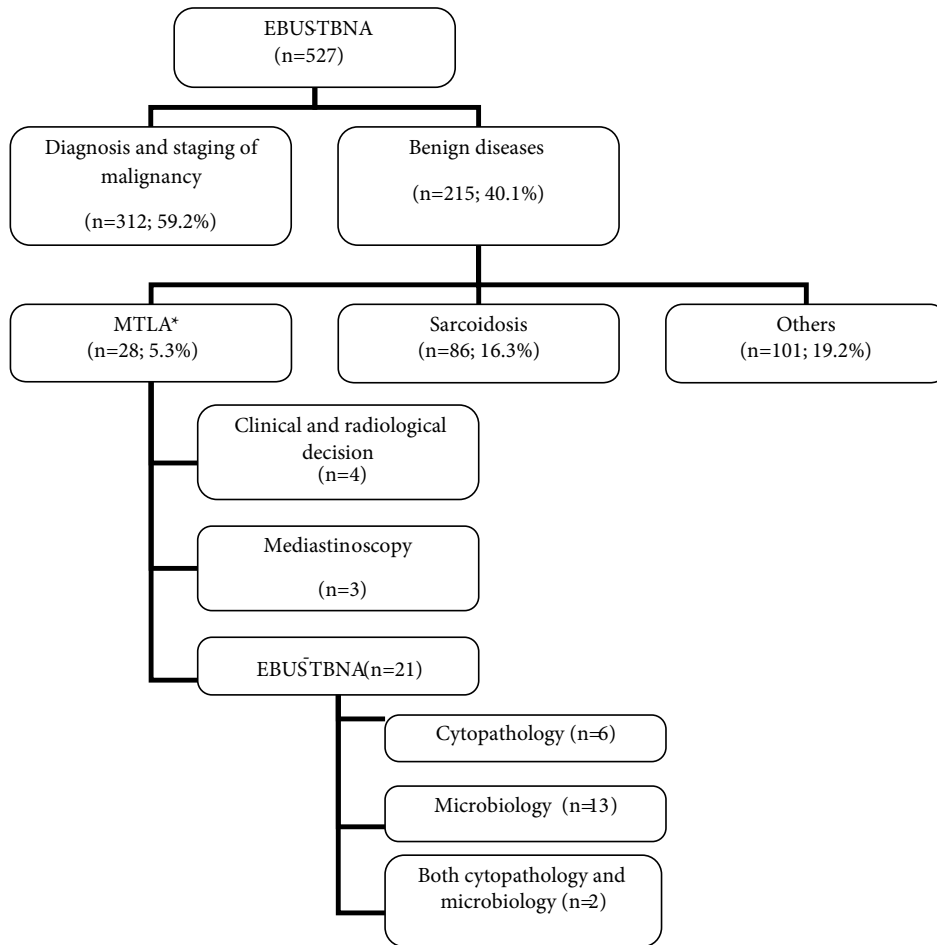


Figure. Diagnostic work-up for patients diagnosed with mediastinal tuberculous lymphadenitis.

Table 1. Characteristics of patients and number and station of sampled lymph nodes.

Sex	
Male	10 (35.7%)
Female	18 (64.3%)
Age, years, mean ± SD	53.4 ± 15.9
Number of sampled lymph nodes	
1	3 (10.7%)
2	15 (53.6%)
3	10 (35.7%)
The most sampled lymph node stations	
Subcarinal	23 (76.7%)
Right lower paratracheal	21 (70%)
Left lower paratracheal	9 (30%)
Left interlobar	7 (28.3%)
Right upper paratracheal	4 (13.3%)
Right interlobar	3 (10%)
Left hilar	1 (3.3%)

In 6 patients EBUS-TBNA cytopathological examination revealed granulomatous inflammation with necrosis. In 2 patients both one of the microbiological tests was positive for *M. tuberculosis* and cytopathology reported necrotizing granulomatous inflammation (Table 2; Figure).

The remaining three patients (10.7%) were diagnosed by mediastinoscopy and 4 (14.3%) patients received treatment according to clinical and radiologic decisions (Figure). These 4 patients were excluded from the statistical analysis despite good response to antituberculosis therapy.

The sensitivity of microbiological examination of EBUS-TBNA samples alone for the diagnosis of MTLA was 62.5% (15/24 cases). The sensitivity of cytopathological examination alone was 33.3%. Sensitivity, specificity, positive predictive value (PPV), NPV, and accuracy of combined cytopathological and microbiological examinations of EBUS-TBNA in the diagnosis of MTLA were 87.5%, 98.5%, 91.4%, 98%, and 94.4%, respectively. There were no major complications.

Table 2. Microbiological and cytopathological results of MTLA patients.

N	EBUS PCR	Sputum		EBUS		EBUS-TBNA histopathology			Med	
		AFB	Cx	AFB	Cx	NGI	GI	A	AFB	Cx
1	-	-	-	-	-	+			Ø	Ø
2	-	-	+	-	-	+			Ø	Ø
3	+	-	-	-	-			+	Ø	Ø
4	-	-	-	-	-			+	Ø	Ø
5	-	-	-	-	+			+	Ø	Ø
6	-	-	-	-	-		+		Ø	Ø
7	-	-	-	+	+		+		Ø	Ø
8	-	+	-	+	+	+			Ø	Ø
9 ^a	Ø	-	-	-	-		+		-	-
10	Ø	-	-	-	+			+	Ø	Ø
11	-	-	-	+	+	+			Ø	Ø
12	+	-	-	-	-			+	Ø	Ø
13	Ø	-	-	-	+		+		Ø	Ø
14	-	-	-	-	-		+		Ø	Ø
15	-	-	-	-	-	+			Ø	Ø
16	+	-	-	+	+		+		Ø	Ø
17 ^a	-	-	-	-	-		+		-	+
18 ^a	-	-	-	-	-		+		-	-
19	Ø	-	-	-	-	+			Ø	Ø
20	-	-	-	-	-	+			Ø	Ø
21	-	-	-	-	+		+		Ø	Ø
22	Ø	-	-	-	+		+		Ø	Ø
23 ^b	-	-	-	-	-	+			-	+
24	-	-	-	-	+		+		Ø	Ø
25	-	-	+	-	+		+		Ø	Ø
26	+	-	-	-	+		+		Ø	Ø
27	-	-	-	-	+		+		Ø	Ø
28	Ø	-	-	-	-			+	Ø	Ø
Total	4	1	2	4	13	8	14	6	0	2

MTLA: Mediastinal tuberculous lymphadenitis. Med: Mediastinoscopy.

AFB: Acid-fast bacilli. Cx: Culture for *M. tuberculosis*. PCR: Polymerase chain reaction.

Ø: Not applicable. GI: Granulomatous inflammation. NGI: Necrotizing granulomatous inflammation.

A: Results other than G and NG.

^a: Mediastinoscopic sample pathology is NGI.

^b: Mediastinoscopic sample pathology is GI.

4. Discussion

In this study we evaluated the diagnostic accuracy of EBUS-TBNA in the diagnosis of MTLA.

In our study, AFB positivity was 14.3% and culture positivity was 46.4% in materials obtained from EBUS-TBNA. In published data, AFB detection ranged from

0.8% to 48.5%, while culture positivity ranged from 20% to 62% (10–17). When these results are compared with fine-needle aspiration results for peripheral lymph nodes and EUS studies for mediastinal lymph nodes, sensitivities and specificities are similar (2,18–21). As a result, conventional microbiological methods have low diagnostic sensitivity

for the diagnosis of MTLA, mostly due to a low burden of bacilli and insufficient sample amount (22).

In recent years, NAATs, like PCR, are being used in the diagnosis of EPT. PCR can detect even very few bacilli and contribute greatly to the diagnosis (5). NAATs are more sensitive than AFB and faster than cultures. In published studies, PCR has a sensitivity of 17%–100% and specificity of 67%–100% in the diagnosis of tuberculous lymphadenitis (23). For EBUS-TBNA-obtained material NAAT positivity was between 18.2% and 56.7% (11,15–17). In a policy update published by the WHO, Xpert MTB/RIF was proposed as a replacement test for the usual practice (including conventional microscopy, culture, or histopathology) for testing specific nonrespiratory specimens (lymph nodes and other tissues) from patients with suspected tuberculosis (24).

In our study, the sensitivity and specificity of NAATs was 14.2% and 99.6%, and the results were similar to those of other studies (11,15–17). It is remarkable that in our study only one out of 4 patients with positive EBUS-TBNA-obtained AFB and two out of 13 patients with positive EBUS-TBNA-obtained culture for *M. tuberculosis* had positive PCR. These results confirm the low sensitivity of PCR. In our study there were also two false positive results. One of these patients had previous antituberculosis treatment. The other was diagnosed with squamous lung cancer. PCR can produce a false positive result due to contamination or inability to distinguish between dead and live bacilli. This is especially observed with DNA-PCR and in patients who had previous tuberculous treatment (25).

Microbiological methods have low sensitivity in the diagnosis of MTLA. Therefore, cytopathological examination of EBUS-TBNA samples is important. Existence of granulomatous inflammation with necrosis, and multinucleated giant cells in aspiration cytology and cellblock, are considered diagnostic for MTLA (11). In cases where only granulomatous inflammation is

observed, differential diagnosis for other possible causes, like sarcoidosis, must be made.

In our study, the cytopathological evaluation of EBUS-TBNA samples revealed necrotizing granulomatous inflammation in 8 (28.6%) cases and granulomatous inflammation without necrosis in 14 (50%) cases. In previous studies, the incidence of necrotizing granulomatous inflammation varied between 27% and 66.7% (10–16).

When microbiological and cytopathological methods are used together, the sensitivity of EBUS-TBNA in MTLA diagnosis increases. In our study, when microbiological and cytopathological results were evaluated together, EBUS-TBNA was diagnostic in 21 cases, and the sensitivity of EBUS-TBNA increased to 87.5%. In previous studies, this sensitivity varied between 70% and 90% (10–17).

Published studies reveal that the most affected lymph nodes are right hilar and paratracheal lymph nodes (26–28). In our study, the most affected lymph nodes were subcarinal, followed by lower right paratracheal lymph nodes.

Our study has some limitations. Retrospective design and lower sample size are two of these limitations. The last limitation is the ‘other’ 101 patients with benign conditions. Anthracosis, pneumoconiosis, and reactive adenitis are coded as ‘other benign’. These patients were followed for at least 1 year. Though we are confident about the final diagnosis of most of the patients, there is still a possibility of misdiagnosis of MTLA as reactive adenitis, especially if EBUS-TBNA cytology was not reported as granulomatous inflammation.

In conclusion, EBUS-TBNA is a safe and well tolerated procedure in the diagnosis of MTLA. Upon suspicion, both microbiological and cytopathological examinations of EBUS-TBNA samples should be performed. When microbiology is combined with cytopathological examination, EBUS-TBNA demonstrates good diagnostic accuracy for the diagnosis of MTLA.

References

1. Sharma SK, Mohan A. Extrapulmonary tuberculosis. *Indian J Med Res* 2004; 120: 316-353.
2. Salvador F, Los-Arcos I, Sanchez-Montalva A, Tortola T, Curran A, Villar A, Saborit N, Castellvi J, Molina I. Epidemiology and diagnosis of tuberculous lymphadenitis in a tuberculosis low-burden country. *Medicine* 2015; 94: 1-6.
3. TB CARE I. International Standards for Tuberculosis Care. 3rd ed. The Hague, the Netherlands: TB CARE I; 2014.
4. Fontanilla JM, Barnes A, Fordham von Reyn C. Current diagnosis and management of peripheral tuberculous lymphadenitis. *Clin Infect Dis* 2011; 53: 555-562.
5. Lee JY. Diagnosis and treatment of extrapulmonary tuberculosis. *Tuberculosis and Respiratory Diseases* 2015; 78: 47-55.
6. Jacob B, Parsa R, Frizzell R, Mearns A, Smith P. Mediastinal tuberculosis in Bradford, United Kingdom: the role of mediastinoscopy. *Int J Tuberc Lung D* 2011; 15: 240-245.
7. Jalil BA, Yasufuku K, Khan AM. Uses, limitations, and complications of endobronchial ultrasound. *Baylor University Medical Center Proceedings* 2015; 28: 325-330.
8. Tortoli E, Cichero P, Piersimoni C, Simonetti MT, Gesu G, Nista D. Use of BACTEC MGIT 960 for recovery of mycobacteria from clinical specimens: multicenter study. *J Clin Microbiol* 1999; 37: 3578-3582.

9. Koneman EW, Allen SD, Janda WM, Schreckenberger PC, Winn WC. *Mycobacteria*. In: *Color Atlas and Textbook of Diagnostic Microbiology*. 4th ed. Philadelphia, PA, USA: J. B. Lippincott Company; 1992. pp. 703-755.
10. Navani N, Molyneaux PL, Breen RA, Connell DW, Jepson A, Nankivell M, Brown JM, Morris-Jones S, Ng B, Wickremasinghe M et al. Utility of endobronchial ultrasound-guided transbronchial needle aspiration in patients with tuberculous intrathoracic lymphadenopathy: a multicentre study. *Thorax*. 2011; 66: 889-893.
11. Hassan T, McLaughlin AM, O'Connell F, Gibbons N, Nicholson S, Keane J. BUS-TBNA performs well in the diagnosis of isolated thoracic tuberculous lymphadenopathy. *Am J Resp Crit Care* 2011; 183: 136-137.
12. Sun J, Teng J, Yang H, Li Z, Zhang J, Zhao H, Garfield DH, Han B. Endobronchial ultrasound-guided transbronchial needle aspiration in diagnosing intrathoracic tuberculosis. *Ann Thorac Surg* 2013; 96: 2021-2027.
13. Kuo CH, Lin SH, Lee KY, Chung FT, Feng PH, Hsiung TC, Lo YL, Liu CY, Kuo HP. Algorithmic approach by endobronchial ultrasound-guided transbronchial needle aspiration for isolated intrathoracic lymphadenopathy: a study in a tuberculosis endemic country. *J Formos Med Assoc* 2014; 113: 527-534.
14. Low SY, Koh MS, Ong TH, Phua GC, Anantham D. Use of endobronchial ultrasound-guided transbronchial needle aspiration (EBUS-TBNA) in the diagnosis of granulomatous mediastinal lymphadenopathy. *Ann Acad Med Singap* 2014; 43: 250-254.
15. Madan K, Mohan A, Ayub II, Jain D, Hadda V, Khilnani GC, Guleria R. Initial experience with endobronchial ultrasound-guided transbronchial needle aspiration (EBUS-TBNA) from a tuberculosis endemic population. *Journal of Bronchology and Interventional Pulmonology* 2014; 21: 208-214.
16. Senturk A, Arguder E, Hezer H, Babaoglu E, Kilic H, Karalezli A, Hasanoglu HC. Rapid diagnosis of mediastinal tuberculosis with polymerase chain reaction evaluation of aspirated material taken by endobronchial ultrasound guided transbronchial needle aspiration. *J Invest Med* 2014; 62: 885-889.
17. Geake J, Hammerschlag G, Nguyen P, Wallbridge P, Jenkin GA, Korman TM, Jennings B, Johnson DF, Irving LB, Farmer M et al. Utility of EBUS-TBNA for diagnosis of mediastinal tuberculous lymphadenitis: a multicentre Australian experience. *Journal of Thoracic Disease* 2015; 7: 439-448.
18. Asimacopoulos EP, Berry M, Garfield B, Roesner M, Jepson A, McCarthy J, Kon OM. The diagnostic efficacy of fine-needle aspiration using cytology and culture in tuberculous lymphadenitis. *Int J Tuberc Lung D* 2010; 14: 93-98.
19. Biadlegne F, Tesfaye W, Sack U, Rodloff AC. Tuberculous lymphadenitis in Northern Ethiopia: in a public health and microbiological perspectives. *PLoS One* 2013; 8: e81918.
20. Puri R, Vilmann P, Sud R, Kumar M, Taneja S, Verma K, Kaushik N. Endoscopic ultrasound-guided fine-needle aspiration cytology in the evaluation of suspected tuberculosis in patients with isolated mediastinal lymphadenopathy. *Endoscopy* 2010; 42: 462-467.
21. Berzosa M, Tsukayama DT, Davies SF, Debol SM, Cen YY, Li R, Mallery S. Endoscopic ultrasound-guided fine needle aspiration for the diagnosis of extra-pulmonary tuberculosis. *Int J Tuberc Lung D* 2010; 14: 578-584.
22. Theron G, Peter J, Calligaro G, Meldau R, Hanrahan C, Khalife H, Matinyenya B, Muchinga T, Smith L, Pandie S et al. Determinants of PCR performance (Xpert MTB/RIF), including bacterial load and inhibition, for TB diagnosis using specimens from different body compartments. *Scientific Reports* 2014; 4: 5658.
23. Daley P, Thomas S, Pai M. Nucleic acid amplification tests for the diagnosis of tuberculous lymphadenitis: a systematic review. *Int J Tuberc Lung D* 2007; 11: 1166-1176.
24. World Health Organization. WHO Policy Update: Xpert MTB/RIF Assay for the Diagnosis of Pulmonary and Extrapulmonary TB in Adults and Children. Geneva, Switzerland: World Health Organization; 2013.
25. Mehta PK, Raj A, Singh N, Khuller GK. Diagnosis of extrapulmonary tuberculosis by PCR. *FEMS Immunol Med Mic* 2012; 66: 20-36.
26. Handa U, Mundi I, Mohan S. Nodal tuberculosis revisited: a review. *Journal of Infection in Developing Countries* 2012; 6: 6-12.
27. Curvo-Semedo L, Teixeira L, Caseiro-Alves F. Tuberculosis of the chest. *Eur J Radiol* 2005; 55: 158-172.
28. Burrill J, Williams CJ, Bain G, Conder G, Hine AL, Misra RR. Tuberculosis: a radiologic review. *RadioGraphics* 2007; 27: 1255-1273.