

1-1-2012

Laparoscopic paraovarian cyst removal in a female rhesus macaque

VIJAY KUMAR

ANSHU RAJ

SAMEER RASTOGI

Follow this and additional works at: <https://journals.tubitak.gov.tr/veterinary>



Part of the [Animal Sciences Commons](#), and the [Veterinary Medicine Commons](#)

Recommended Citation

KUMAR, VIJAY; RAJ, ANSHU; and RASTOGI, SAMEER (2012) "Laparoscopic paraovarian cyst removal in a female rhesus macaque," *Turkish Journal of Veterinary & Animal Sciences*: Vol. 36: No. 4, Article 22.

<https://doi.org/10.3906/vet-1106-32>

Available at: <https://journals.tubitak.gov.tr/veterinary/vol36/iss4/22>

This Article is brought to you for free and open access by TÜBİTAK Academic Journals. It has been accepted for inclusion in Turkish Journal of Veterinary & Animal Sciences by an authorized editor of TÜBİTAK Academic Journals. For more information, please contact academic.publications@tubitak.gov.tr.

Laparoscopic paraovarian cyst removal in a female rhesus macaque

Vijay KUMAR^{1*}, Anshu RAJ², Sameer RASTOGI¹

¹Dhauladhar Nature Park, Gopalpur, Distt-Kangra, Himachal Pradesh, 176059 - INDIA

²Veterinary Hospital, Deol, Baijnath, Distt-Kangra, Himachal Pradesh, 176125 - INDIA

Received: 25.06.2011 • Accepted: 06.10.2011

Abstract: A 15-year-old female rhesus macaque was showing signs of bleeding from the vulva, while no other signs were noted. The animal was treated symptomatically with no improvement. On abdominal laparoscopy, a small transparent growth was discovered on both of the uterine horns, between the ovaries and fallopian tubes, and after thorough examination was diagnosed as a paraovarian cyst. The left cyst was larger (5-6 cm) than the right cyst (3-4 cm). Both of the cysts were smooth and transparent due to accumulated fluid. The cysts were aspirated and removed by bipolar laparoscopy cauterization.

Key words: Laparoscopy, paravarian cyst, electrocauterization, rhesus macaque

Introduction

Paraovarian cysts represent approximately 10% of adnexal masses (1). They are usually small and asymptomatic, although they are occasionally large, resulting in pelvic pain (2). Paraovarian cysts are an occasional finding during surgery, although they are rarely appreciated (3). Laparoscopic cystectomy involves removing the cysts without opening the abdomen. Since the advancement of operative laparoscopy, it has been utilized in various surgical interventions worldwide. Operative laparoscopy is a safe and less expensive approach than laparotomy for the surgical removal of ovarian cysts (4). Laparoscopic surgery is recommended when cysts are small, while in cases of larger cysts, laparotomy is utilized by various surgeons for humans as well as animals. In the present case, both of the paraovarian cysts were removed by laparoscopic electrocauterization.

Case history

A 15-year-old female rhesus macaque was captured in a state population control program. The animal was showing signs of mucoid mixed bleeding from the vagina with swelling on the vulvar areas. The animal was treated with hemostat and multivitamin injections with no improvement. The animal was healthy without other signs of the diseased condition. All of the physiological and clinical parameters were normal and the blood hematological values of the animal were within normal levels.

Anesthesia was performed using ketamine 10 mg/kg (100 mg/mL) and xylazine 2 mg/kg bodyweight (100 mg/mL) in a squeeze cage. The animal was placed in the Trendelenburg's position on a surgical table. On the left and right sides, 5-6 cm from ventral midline, 1 pre-umbilical midline and 2 lateral ports were created. Pneumoperitoneum was achieved

* E-mail: drvijay0220@gmail.com

by carbon dioxide with a pressure gradient of 10 mmHg. A canula was inserted in the midline port and a telescope (5 mm diameter, Frontline Limited, Germany) connected to a light source was inserted. On laparoscopic intra-abdominal examination a small transparent growth was discovered on both of the uterine horns, between the ovaries and fallopian tubes, and after thorough examination was diagnosed as a paraovarian cyst. The left cyst was 5-6 cm in size, while the right cyst was 3-4 cm in size (Figure 1).

Results and discussion

The cysts were smooth and transparent due to accumulated fluid. They were deflated by removing the fluid, using a suction needle (Figure 2). Bipolar forceps and a scissors were inserted through the lateral ports. The deflated cysts were grasped and elevated with the help of bipolar forceps and cauterization and cutting of the cyst was achieved by using bipolar cautery (Figure 3), and the dissected cyst was carefully pulled out through the canula. There was minimal blood loss with this procedure. After complete removal of the cysts, the area was checked for bleeding. The muscles and skin were sutured using vicryl suture (3-0). The animal was given injections of enrofloxacin at 10 mg/kg bodyweight (intramuscularly) and meloxicam at 0.25 mg/kg bodyweight, for 5 days. All of the surgical wounds healed without any complications.

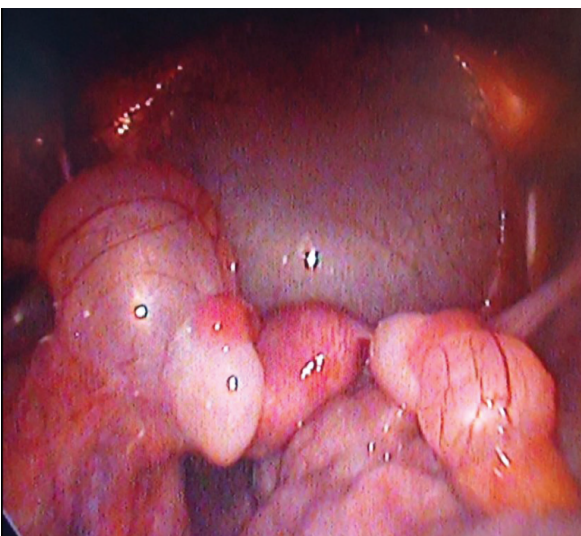


Figure 1. Paraovarian cyst.

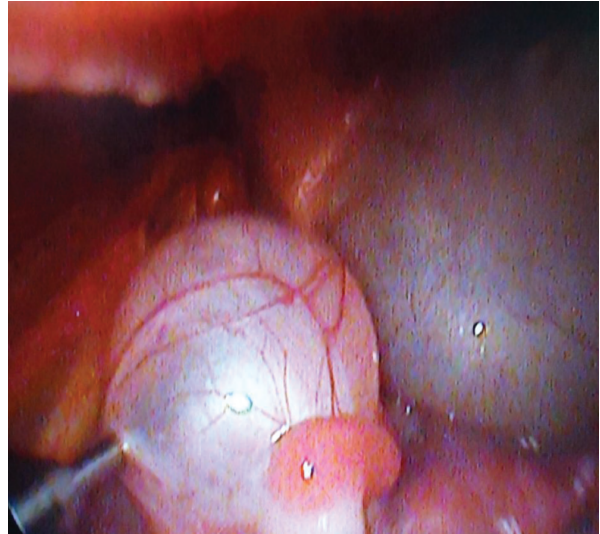


Figure 2. Aspiration of fluid from a cyst.

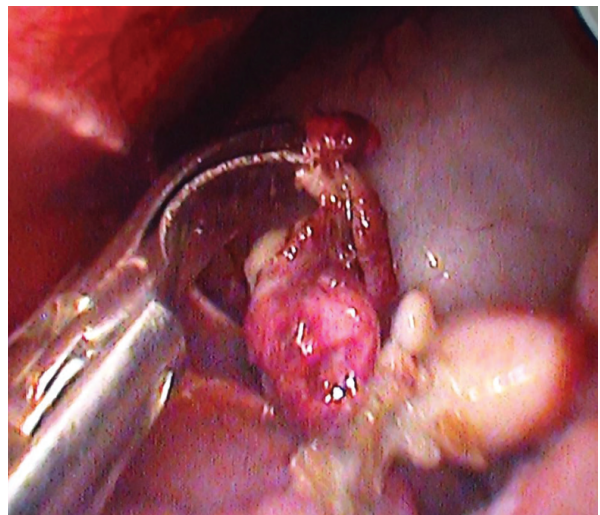

Figure 3. Cutting and coagulation of paraovarian cyst.

Diagnosis of an ovarian cyst is quite difficult due to the lack of specific symptoms and signs. After diagnosis of the cyst, the treatment decision regarding the surgical approach depends on the size of the cyst, its location in the abdominal cavity, and eventually the surgeon's level of experience in minimal access surgery. Paraovarian cysts are usually small in size and single, and bilateral cysts have also been reported in human females (5). In the present case we also found bilateral cysts in a female rhesus macaque. The left paraovarian cyst was 5-6 cm in size,

while the right paraovarian cyst was 3-4 cm in size. If the cysts are larger, the best method of removal is laparotomy. Laparoscopic methods of cyst removal are only utilized for small cysts (6). A paraovarian cyst in a rhesus macaque was also reported by Green et al. (7). In the present case, both of the paraovarian cysts ranged in size from 3 to 6 cm; therefore, the laparoscopic method was utilized for the complete surgical excision of the cysts. A cyst has previously

also been removed effectively by laparoscopic electrocauterization in a mare (8). Old age may be the reason for the presence of the cyst in the present case. The laparoscopic method permitted clear diagnosis and visualization of the cystic structure, while electrocauterization completely controlled the bleeding. It was concluded that minimally invasive surgery can be performed safely and effectively in removal of small ovarian cysts in the rhesus macaque.

References

1. Barloon, T.J., Brown, B.P., Abu-Yousef, M.M., Warnock, N.G.: Paraovarian and paratubal cysts: preoperative diagnosis using transabdominal and transvaginal sonography. *J. Clin. Ultrasound*, 1996; 24: 117-22.
2. Grant, E.C.: Benign conditions of the ovaries. In: Nyberg D.A., Hill L.M., Bohm-Velez M., Mendelson E.B., Eds. *Transvaginal ultrasound*. St Louis, MO: Mosby-Year Book, 1992; 199.
3. Gopal, K., Lim, Y., Dobson, M., Keating, P., Stringfellow, H.: A case of torted parafimbrial cyst on MRI: case report and review of the literature. *Brit. J. Radiology*, 2006; 79: 208-210.
4. Bulletti, C., Seracchioli, R., Polli, V: Financial impact in the Italian Health Service of laparoscopic versus laparotomic surgery for the treatment of ovarian cysts. *Hum. Reprod.*, 1996; 11: 287-290.
5. Genardy, R., Parmley, T., Woodruff J.D.: The origin and clinical behaviour of the paraovarian tumor. *Am. J. Obstet. Gynecol.*, 1977; 129: 873-80.
6. Atef, M., Darwish, M.D., Ahmad, F., Amin, M.D., Safwat, A.: Mohammad, M.D: Laparoscopic Management of Paratubal and Paraovarian Cysts. *J. Soc. Laparoendoscopic Surg.*, 2003; 7: 101-106.
7. Green, S.L., Tolwani, R.J., Waggle, K.S., Otto, G.M.: Endometriosis and a paraovarian cyst in a rhesus macaque. *Vet. Radiol. Ultrasound*, 1999; 40: 271-274
8. Rambags, B.P.B., Stout, T.A.E.: Transcervical endoscope-guided emptying of a transmural uterine cyst in a mare. *Vet. Record*, 2005; 156: 679-682