

1-1-2018

bservational study of dermatological manifestations in patients admitted to a tertiary poison center in Iran

HALEH TALAIE

SOHEILA NASIRI

MEHDI GHEISARI

SAHAR DADKHAHFAR

SOMA AHMADI

Follow this and additional works at: <https://journals.tubitak.gov.tr/medical>



Part of the [Medical Sciences Commons](#)

Recommended Citation

TALAIE, HALEH; NASIRI, SOHEILA; GHEISARI, MEHDI; DADKHAHFAR, SAHAR; and AHMADI, SOMA (2018) "bservational study of dermatological manifestations in patients admitted to a tertiary poison center in Iran," *Turkish Journal of Medical Sciences*: Vol. 48: No. 1, Article 23. <https://doi.org/10.3906/sag-1707-141>

Available at: <https://journals.tubitak.gov.tr/medical/vol48/iss1/23>

This Article is brought to you for free and open access by TÜBİTAK Academic Journals. It has been accepted for inclusion in Turkish Journal of Medical Sciences by an authorized editor of TÜBİTAK Academic Journals. For more information, please contact academic.publications@tubitak.gov.tr.

Observational study of dermatological manifestations in patients admitted to a tertiary poison center in Iran

Hale TALAIE¹, Soheila NASIRI^{2*}, Mehdi GHEISARI², Sahar DADKHAHFAR², Soma AHMADI²

¹Shahid Beheshti University of Medical Sciences, Tehran Loghman Hakim Hospital & Toxicological Research Center, Tehran, Iran

²Skin Research Center, Shahid Beheshti University of Medical Sciences, Tehran, Iran

Received: 27.07.2017 • Accepted/Published Online: 31.12.2017 • Final Version: 23.02.2018

Background/aim: Acute unintentional and deliberate poisoning by medications and chemicals is a frequent emergency, especially in Iran. This study aimed to evaluate the frequency and character of skin findings occurring in patients with acute intentional and unintentional poisoning.

Materials and methods: This prospective observational study was performed at the Loghman Hakim Hospital Poison Center over a period of 6 months from April 2016 to September 2016. Data including patient demographics, cause of poisoning, and level of consciousness were collected. Pediatric patients (under the age of 13) and patients who died in the first hours of admission were excluded from the study.

Results: The most common cause of toxicity-related admission in our patients was methadone overdose. The most common skin finding in these patients was xerosis. According to our results, there was an association between tramadol poisoning and self-induced lesions. Shin hyperpigmentation was found to be significantly more frequent in patients with lead poisoning.

Conclusion: Further study is recommended to shed light on the possible association of drug poisoning and skin lesions.

Key words: Poisoning, cutaneous lesion, opium, methadone

1. Introduction

Acute unintentional and deliberate poisoning by medications and chemicals is a frequent emergency, especially in Iran (1). This might be due to the increase in suicide attempts and drug poisoning being the third cause of death in suicides in our country (2).

Since dermatology is mainly regarded as an outpatient field, dermatological manifestations have not received enough attention in the literature concerning patients with acute emergency conditions, and poisoned patients are not exceptional in this regard. Additionally, skin findings do not seem to affect the course or outcome in patients who are critically ill; therefore, physicians may overlook them (3).

Skin evaluation is a key part of forensic examination that reveals patterns of damage suggesting a specific cause, signs of the internal disease, or other clues (4). On the other hand, many skin conditions are associated with drug abuse and psychiatric disorders, which are both common in poisoned patients (5,6).

To our best knowledge, no reports on the incidence and character of skin lesions in patients admitted to the

poisoning centers exist. In order to evaluate the frequency and character of skin findings occurring in patients with acute intentional and unintentional poisoning, we performed this prospective cross-sectional study.

2. Materials and methods

2.1. Settings and participants

We performed this prospective observational study at the Loghman Hakim Hospital Poison Center, which is the largest poison center in Iran with more than 68 years of experience in managing poisoned patients, over a period of 6 months from April 2016 to September 2016. All patients admitted to this center were consecutively evaluated within 48 h of admission in both wards and the intensive care unit. A board-certified dermatologist who was assisted by two dermatology residents receiving their training in dermatology performed the skin examinations.

2.2. Data collection

Patient data were collected with preconstructed forms. Data including patient demographics, cause of poisoning, and level of consciousness were collected. Pediatric patients

* Correspondence: s_nasiri@sbm.ac.ir

(under the age of 13) and patients who died in the first hours of admission were excluded from our study. Patients with more than one drug poisoning were also excluded from our study.

2.3. Descriptive statistics

Descriptive statistical methods were used to summarize demographic and other variables. Skin lesions were categorized into six categories. The first category included skin lesions related to signs of drug abuse, the second category included those related to drug hypersensitivity reactions, skin lesions in the third category concerned those with signs of psychocutaneous disorders, the fourth category was vascular lesions, and the fifth category included lesions involving the nail and mucosa. The sixth category included all other lesions.

Skin lesions were classified into one of the categories as defined above. Patients with more than one cutaneous manifestation belonging to two different categories were counted in both categories.

Institutional research board and ethics committee approval was acquired before initiation of the study. Informed consent was obtained from patients or their next of kin for enrollment in the study.

3. Results

A total of 500 patients were enrolled during the study period.

The mean (\pm SD) age was 36.87 ± 15.96 years with a range of 13–92. There was a slight male predominance with a male : female ratio of 1.43 : 1. The number of patients who were admitted to the ICU poisoning ward was 162 (32.4%) compared to 338 (67.6%) patients who were visited in the wards. Twenty-six (16%) patients of 162 patients who were visited in the ICU ward were in a coma, 110 (67.9%) were in a stupor, and 26 (16%) were conscious.

The Figure shows the drugs that were responsible for poisoning in our patients. The most common drug toxicity was methadone (19.4%), followed by opium (15.8%), tramadol (13.4%), benzodiazepine (12.2%), and lead (8.4%).

The number of patients who had skin lesions was 204 (49.1%). In 40 patients more than one skin lesion was detected. The categories of skin lesions are demonstrated in Table 1.

The most frequent skin lesions in category 1 were ulceration ($n = 8$), palmar hyperkeratosis ($n = 8$), popping scars ($n = 7$), and cellulitis ($n = 5$). In the second category acneiform drug reaction ($n = 10$), fixed drug eruption ($n = 6$), exanthematous drug reactions ($n = 4$), and erythroderma ($n = 1$) were the most frequent diagnoses. In the third category, the most common skin findings were self-injury ($n = 53$), neurotic excoriation ($n = 8$), neglect dermatitis ($n = 2$), and trichotillomania ($n = 1$). In category 4 pigmented purpuric eruption was

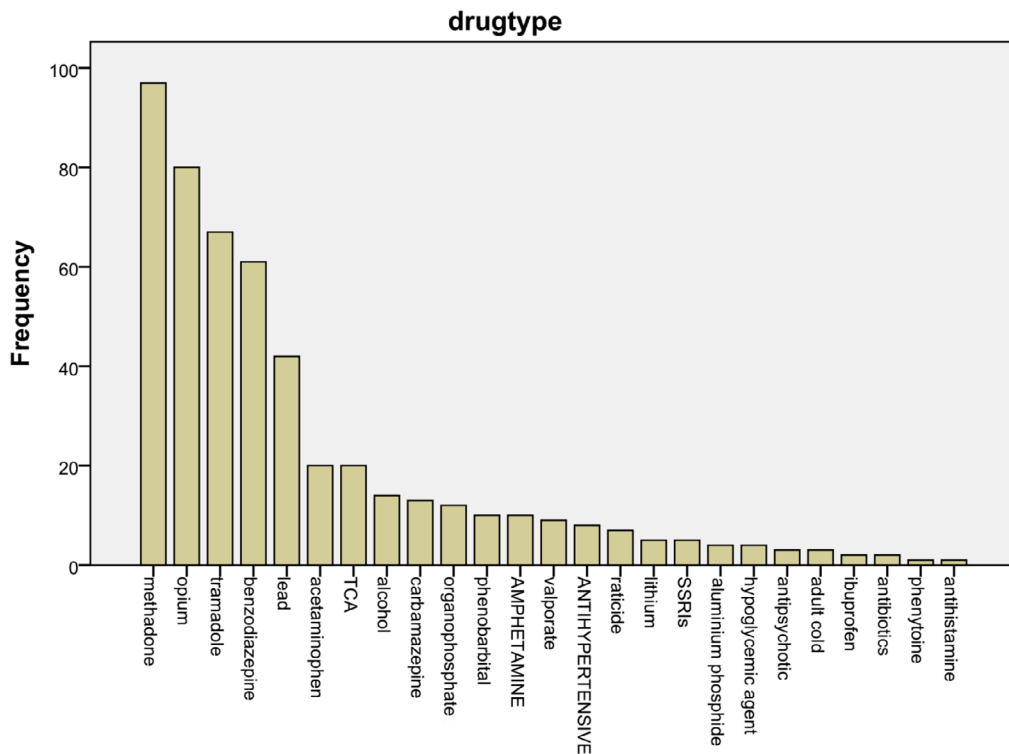


Figure. The documented drug poisonings in order of frequency.

Table 1. Cutaneous manifestations in patients with drug poisoning.

Category 1: Signs of drug abuse	Ulceration (8) Palmar hyperkeratosis (8) Popping scars (7) Skin infections (5) Skin tracks (1)
Category 2: Drug hypersensitivity reactions	Acneiform drug reactions (10) Fixed drug eruption (6) Exanthematous drug reactions (4) Erythroderma (1)
Category 3: Signs of psychocutaneous disorders	Self-injury (53) Excoriation (8) Neglect dermatitis (2) Trichotillomania (1)
Category 4: Vascular lesions	Pigmented purpuric eruptions (7) Petechiae and purpura (1)
Category 5: Nail and mucosal lesions	Nail hyperkeratosis (7) Oral lesions (6) Onycholysis (3)
Category 6: Others	Xerosis (44) Dermatitis (25) Shin hyperpigmentation (14) Urticaria and angioedema (7) Vesiculobullous lesions (5) Hyperhidrosis (3) Psoriasis (2) Palmar erythema (1) Nonfollicular pustules (1)

the most common finding ($n = 7$), followed by petechial and purpuric lesions encountered in one patient. Category 5 included the nail and oral mucosal lesions with nail hyperkeratosis being the most common finding, followed by oral lesions and onycholysis. Interestingly, we found neither involvement of other mucosal sites in our patients nor specific involvement of hair. Table 1 also contains the other skin findings that could not be classified into any of the categories mentioned earlier.

The two-sided asymptotic significance of the chi-square statistic was $P \leq 0.001$. In order to compare column proportions for each row's pair of columns to indicate which pairs of columns in the cross-tabulation were significant, adjusted P-values (Bonferroni method) were utilized. Table 2 shows the results of this analysis.

Table 3 displays the correlation of the most common drugs implicated in our patient with frequently observed skin lesions. Severe xerosis associated with methadone and opium toxicity. This association was significant for methadone. Self-induced lesions were significantly more frequent in patients with tramadol toxicity. Shin hyperpigmentation showed a strong association with lead toxicity.

4. Discussion

This study aimed to illustrate skin findings in patients admitted to a poisoning ward. It is a unique study conducted with a significant number of patients in the largest poison center in Iran (1).

The most important finding of our study is that cutaneous findings, although helpful, are not adequate to determine the specific cause of drug poisoning. Most of the skin lesions in our study could not be related to drug toxicity per se. This finding can be explained by the fact that many acute poisonings are deliberate self-poisonings that are dynamic medical illnesses representing an acute exacerbation of a chronic underlying psychosocial disorder (7).

Previous reports on the dermatologic manifestations of drug poisonings were limited to case reports and small case series (8). Interestingly, the incidence of bullous eruptions was lower than expected based on traditional concepts (9,10). It seems that occurrence of bullous lesions in intoxicated patients has declined in recent years; this may be due to the change in the trends of most common drug poisonings (11).

Table 2. The results of Bonferroni analysis to find the significant correlations between various categories of skin lesions and drug types.

Drug type		Skin lesion category					
		1	2	3	4	5	6
Opium	Count	N = 3	N = 2	N = 13	N = 4	N = 4	N = 13
	Percent	7.7%	5.1%	33.3%	10.3%	10.3%	33.3%
Methadone	Count	N = 6	N = 1	N = 10	N = 1	N = 2	N = 18
	Percent	15.8	2.6	26.3	2.6%	5.3	47.4
Tramadol	Count	N = 2	N = 5	N = 23	N = 0	N = 0	N = 2
	Percent	6.3	15.6	71.9	0.0	0.0%	6.3
Acetaminophen	Count	N = 0	N = 0	N = 1	N = 0	N = 0	N = 1
	Percent	0.0	0.0%	50.0	0.0%	0.0	50.0
Phenobarbital	Count	N = 0	N = 3	N = 1	N = 0	N = 0	N = 1
	Percent	0.0	60.0	20.0	0.0	0.0	20.0
Sodium valproate	Count	N = 0	N = 1	N = 0	N = 1	N = 0	N = 0
	Percent	0.0	50.0	0.0	50.0	0.0	0.0
Benzodiazepines	Count	N = 0	N = 0	N = 8	N = 1	N = 3	N = 6
	Percent	0.0	0.0	44.4	5.6	16.7	33.3
Lithium	Count	N = 0	N = 3	N = 0	N = 0	N = 0	N = 0
	Percent	0.0	100.0	0.0	0.0	0.0	0.0
TCA	Count	N = 0	N = 0	N = 1	N = 0	N = 0	N = 11
	Percent	0.0	0.0	8.3	0.0	0.0	91.7
Alcohol	Count	N = 1	N = 0	N = 1	N = 0	N = 0	N = 4
	Percent	16.7	0.0	16.7	0.0	0.0	66.7
Lead	Count	N = 1	N = 0	N = 0	N = 0	N = 2	N = 17
	Percent	5.0	0.0	0.0	0.0	10.0	85.0
Carbamazepine	Count	N = 1	N = 5	N = 0	N = 0	N = 0	N = 0
	Percent	16.7	83.3	0.0	0.0	0.0	0.0
Antipsychotics	Count	N = 0	N = 0	N = 1	N = 0	N = 0	N = 0
	Percent	0.0	0.0	100.0	0.0	0.0	0.0
Organophosphate	Count	N = 0	N = 0	N = 0	N = 0	N = 0	N = 3
	Percent	0.0%	0.0%	0.0%	0.0%	0.0%	100.0%
Hypoglycemic agents	Count	N = 1	N = 0	N = 0	N = 0	N = 0	N = 1
	Percent	50.0	0.0	0.0	0.0	0.0	50.0
SSRIs	Count	N = 0	N = 0	N = 1	N = 0	N = 0	N = 0
	Percent	0.0	0.0	100.0	0.0	0.0	0.0
Amphetamine	Count	N = 0	N = 0	N = 4	N = 0	N = 0	N = 0
	Percent	16.7	0.0	66.7	0.0	0.0	16.7
Total	Count	16	20	64	7	11	78
	Percent	8.2	10.2	32.7	3.6	5.6	39.8

Table 3. The correlation of the most common drugs implicated in our patients with frequently observed skin lesions.

Most common drugs	Most common skin lesions					
	Self-induced lesions	Severe xerosis	Shin hyperpigmentation	Ulceration	Acneiform lesions	Others
Opium	N = 7	N = 9	N = 0	N = 0	N = 1	N = 22
	15.2%	33.3%	0.0%	0.0%	100.0%	37.9%
Methadone	N = 11	N = 14	N = 0	N = 0	N = 0	N = 13
	23.9%	51.9%	0.0%	0.0%	0.0%	22.4%
Tramadol	N = 22	N = 1	N = 0	N = 1	N = 0	N = 9
	47.8%	3.7%	0.0%	100.0%	0.0%	15.5%
BZD	N = 6	N = 1	N = 0	N = 0	N = 0	N = 11
	13.0%	3.7%	0.0%	0.0%	0.0%	19.0%
Lead	N = 0	N = 2	N = 14	N = 0	N = 0	N = 3
	0.0%	7.4%	100.0%	0.0%	0.0%	5.2%

The most common cause of toxicity-related admission in our patients was methadone overdose. The most common skin finding in these patients was xerosis. According to the study by Haber et al., skin symptoms are common in patients receiving methadone (12). Since many of the patients with methadone overdose are addicts, the role of methadone in developing skin dryness needs to be elucidated with further investigations (13).

Another significant finding of our study was the association of tramadol poisoning with self-induced lesions. The study by Bassiony et al. in 2016 was performed to evaluate the most important psychiatric disorders among tramadol abusers. The most common personality disorders among patients in this study were borderline (14). The importance of self-inflicted injuries was emphasized since they might point out highly comorbid conditions, such as borderline and antisocial personality disorders. Our findings support the association between tramadol abuse and self-induced injuries, and both might be caused by underlying borderline personality disorders.

Lead poisoning due to oral ingestion of opium is a well-described condition in Iran (15–18). Lead poisoning has a

variety of cutaneous and some extracutaneous manifestations (19). Burton's lead line is a bluish line on the gingival margin, seen in lead poisoning, and is due to the deposition of lead sulfate resulting from a reaction between sulfur from the oral flora and lead (20).

Chronic lead poisoning results in a typical waxy 'lead hue' with pallor on the skin. Periocular pigmentation and greenish discoloration of the skin due to embedded lead fragments in the skin from bullets have also been described (21).

None of the patients with opium overdose with normal serum lead levels showed shin hyperpigmentation. The mechanism of this phenomenon needs to be elucidated.

This study was a single-center study; therefore, the results cannot be freely generalized to other populations. The lack of accurate documentation in poisoned patients was the other limitation of our study. Additionally, there was a scarcity of literature to be reviewed in this area due to the small number of previous comparable studies.

In conclusion, skin presentations of common drug poisonings are not specific. More studies need to be performed to shed light on the association of drug poisoning with skin lesions.

References

- Hassanian-Moghaddam H, Zamani N, Rahimi M, Shadnia S, Pajoumand A, Sarjami S. Acute adult and adolescent poisoning in Tehran, Iran; the epidemiologic trend between 2006 and 2011. *Arch Iran Med* 2014; 17: 534-538.
- Kiadaliri AA, Saadat S, Shahnavaizi H, Haghparast-Bidgoli H. Overall, gender and social inequalities in suicide mortality in Iran, 2006-2010: a time trend province-level study. *BMJ Open* 2014; 4: e005227.
- Agrawal P, Peter JV, George R. Dermatological manifestations and relationship to outcomes of patients admitted to a medical intensive care unit: a study from a tertiary care hospital in India. *Postgrad Med J* 2013; 89: 501-507.
- Reddy K, Lowenstein EJ. Forensics in dermatology: part I. *J Am Acad Dermatol* 2011; 64: 801-810.

5. Moftah NH, Kamel AM, Attia HM, El-Baz MZ, Abd El-Moty HM. Skin diseases in patients with primary psychiatric conditions: a hospital based study. *J Epidemiol Glob Health* 2013; 3: 131-138.
6. Tse JY, Adisa M, Goldberg LJ, Nazarian RM. Dermatopathologic manifestations of intravenous drug use. *J Cutan Pathol* 2015; 42: 815-823.
7. Daly FF, Little M, Murray L. A risk assessment based approach to the management of acute poisoning. *Emerg Med J* 2006; 23: 396-399.
8. Gordana VE, Zoran Š, Jasmina JS. Benzodiazepine poisoning in elderly. *Vojnosanitetski Pregled* 2016; 73: 234-238.
9. Beveridge G, Lawson A. Occurrence of bullous lesions in acute barbiturate intoxication. *Brit Med J* 1965; 1: 835-837.
10. Mandy S, Ackerman AB. Characteristic traumatic skin lesions in drug-induced coma. *JAMA* 1970; 213: 253-256.
11. Goksu S, Yildirim C, Kocoglu H, Tutak A, Oner U. Characteristics of acute adult poisoning in Gaziantep, Turkey. *J Toxicol-Clin Toxic* 2002; 40: 833-837.
12. Haber PS, Elsayed M, Espinoza D, Lintzeris N, Veillard AS, Hallinan R. Constipation and other common symptoms reported by women and men in methadone and buprenorphine maintenance treatment. *Drug Alcohol Depend* 2017; 181: 132-139.
13. Eizadi-Mood N, Yaraghi A, Sharifian Z, Feizi A, Hedaiaty M, Sabzghabae AM. Clinical presentation and the outcome of therapy in a cohort of patients with methadone toxicity in Iran. *Materia Socio Medica* 2015; 27: 276-279.
14. Bassiony MM, Youssif UM, Hussein RA, Saeed M. Psychiatric comorbidity among Egyptian patients with opioid use disorders attributed to tramadol. *J Addict Med* 2016; 10: 262-268.
15. Zamani N, Jamshidi F. Abuse of lead-contaminated opium in addicts. *Singapore Med J* 2012; 53: 698.
16. Karrari P, Mehrpour O, Abdollahi M. A systematic review on status of lead pollution and toxicity in Iran; guidance for preventive measures. *DARU* 2012; 20: 2.
17. Khatibi-Moghadam H, Khadem-Rezaiyan M, Afshari R. Comparison of serum and urine lead levels in opium addicts with healthy control group. *Hum Exp Toxicol* 2016; 35: 861-865.
18. Meybodi FA, Eslick GD, Sasani S, Abdolhoseyni M, Sazegar S, Ebrahimi F. Oral opium: an unusual cause of lead poisoning. *Singapore Med J* 2012; 53: 395-397.
19. De Caluwe JP. Lead poisoning caused by prolonged use of kohl, an underestimated cause in French-speaking countries. *J Fr Ophtalmol* 2009; 32: 459-463 (in French with abstract in English).
20. Kluger N, Frances P. Bluish pigmentation of the gingiva in a homeless patient: a quiz. Burton's line revealing chronic lead poisoning (plumbism). *Acta Derm Venereol* 2012; 92: 109-110.
21. Mahta A, Kesari S. The greens of lead. *QJM-Int J Med* 2012; 105: 1223.