

1-1-2011

## Calcitonin-induced alterations to the ultimobranchial and parathyroid glands in the garden lizard *Calotes versicolor*

AJAI K. SRIVASTAV

BHAWNA SRIVASTAVA

DIWAKAR MISHRA

SUNIL K. SRIVASTAV

NOBUO SUZUKI

Follow this and additional works at: <https://journals.tubitak.gov.tr/zoology>



Part of the [Zoology Commons](#)

---

### Recommended Citation

SRIVASTAV, AJAI K.; SRIVASTAVA, BHAWNA; MISHRA, DIWAKAR; SRIVASTAV, SUNIL K.; and SUZUKI, NOBUO (2011) "Calcitonin-induced alterations to the ultimobranchial and parathyroid glands in the garden lizard *Calotes versicolor*," *Turkish Journal of Zoology*. Vol. 35: No. 1, Article 2. <https://doi.org/10.3906/zoo-0807-30>

Available at: <https://journals.tubitak.gov.tr/zoology/vol35/iss1/2>

This Article is brought to you for free and open access by TÜBİTAK Academic Journals. It has been accepted for inclusion in Turkish Journal of Zoology by an authorized editor of TÜBİTAK Academic Journals. For more information, please contact [academic.publications@tubitak.gov.tr](mailto:academic.publications@tubitak.gov.tr).

## Calcitonin-induced alterations to the ultimobranchial and parathyroid glands in the garden lizard *Calotes versicolor*

Ajai K. SRIVASTAV<sup>1,\*</sup>, Bhawna SRIVASTAVA<sup>1</sup>, Diwakar MISHRA<sup>1</sup>,

Sunil K. SRIVASTAV<sup>1</sup>, Nobuo SUZUKI<sup>2</sup>

<sup>1</sup>Department of Zoology, D.D.U. Gorakhpur University, Gorakhpur 273009 - INDIA

<sup>2</sup>Noto Marine Laboratory, Institute of Nature and Environmental Technology,  
Kanazawa University, Ogi, Noto-cho, Ishikawa 927-0553 - JAPAN

Received: 29.07.2008

**Abstract:** *Calotes versicolor* specimens were divided into 2 groups of equal quantity (groups A and B). Group A was injected daily with 0.1 mL/50 g bw of vehicle. Group B was injected daily with 0.5 µg/50 g bw of salmon calcitonin. Lizards in each group were sacrificed 2 h after the last injection on the 1st, 3rd, 5th, 10th, and 15th day of treatment. After collection of blood samples, ultimobranchial and parathyroid glands were fixed.

The plasma calcium level in the lizards treated with calcitonin decreased on day 1. This response progressed up to day 5; thereafter the level was elevated, so that on day 15 a normal plasma calcium level was achieved. No change in plasma phosphate levels from day 1 was observed following calcitonin treatment. Progressive hypophosphatemia was observed from day 3 to 5; thereafter the level tended to rise and resulted in normophosphatemia on day 15.

The ultimobranchial gland in the lizards treated with calcitonin did not exhibit any histological alterations up to day 5. The nuclear volume of ultimobranchial cells decreased on day 10 and persisted until day 15. Additionally, few degenerating cells were observed after 15 days of calcitonin treatment. The parathyroid gland in *C. versicolor* was unaffected up to day 3 following calcitonin treatment. A progressive increase in the nuclear volume of parathyroid cells was observed from day 5 until the end of the experiment (day 15); the gland became compact on days 10 and 15. In addition, few degenerating cells were observed after 15 days of calcitonin treatment.

**Key words:** Calcitonin, ultimobranchial gland, parathyroid gland, lizard, plasma calcium, plasma phosphate, *Calotes versicolor*

### Introduction

The ultimobranchial gland in vertebrates is derived from the pharyngeal pouch epithelium during development and secretes calcitonin (CT). The gland is either separately located (non-mammalian

vertebrates) or embedded in the thyroid (mammals). It is noteworthy that CT-like substances have also been found in invertebrates, as well as in the brain, liver, gut, thymus, and other tissues in vertebrates (Srivastav et al., 2008). The presence of CT-like cells in

\* E-mail: ajaisrivastav@hotmail.com

the pharynx of protochordates and crustaceans seems to be significant, which indicates that CT-like cells are precursors of calcitonin cells (Srivastav et al., 2008). CT is an ancient hormone that appeared early in evolution, which is evident by the demonstration of human CT-like molecules in unicellular organisms (*Escherichia coli*, *Candida albicans*, and *Aspergillus fumigatus*).

The true parathyroid glands (PTGs) are not present in all vertebrate groups. Aquatic vertebrates (i.e. fishes and amphibians living predominantly in water) do not possess PTGs (Wendelaar et al., 1991). PTGs are closely associated with the thyroid in mammals (Dacke, 1979), whereas in non-mammalian vertebrates these glands are not closely associated with the thyroid. It is clear that the functional aspects of these glands in most reptiles, at least with respect to blood calcium response, are similar to those of higher vertebrates, i.e. birds and mammals (Srivastav et al., 1995).

The physiological role of CT in reptiles remains unclear. Several investigators have tried to demonstrate a hypocalcemic effect of CT (secreted by the ultimobranchial gland in non-mammals) in reptiles; however, the results were inconsistent (Srivastav et al., 1998, 2008). Administration of mammalian CT had no effect on plasma calcium in turtles (Clark, 1965), snakes (Clark, 1971), or lizards (Dix et al., 1970; Kiebzak and Minnick, 1982). In contrast, administration of salmon CT resulted in hypocalcemia in young iguanas (Kline, 1981) and snakes (Srivastav et al., 1986; Srivastav and Rani, 1989a; Hasan et al., 1992).

The present study aimed to examine the effect of calcitonin administration on the ultimobranchial and PTGs in the garden lizard *Calotes versicolor*. Changes in plasma calcium and inorganic phosphate levels were also observed and accounted for.

## Materials and methods

*Calotes versicolor* specimens (both sexes, bw 23-32 g) were procured during May and acclimatized under laboratory conditions for 1 week. The animals were divided 2 groups (groups A and B) of 50 specimens each. Specimens in group A were intraperitoneally injected daily with 0.1 mL/50 g bw of vehicle (0.1 M

acetate buffer at pH 4.3, containing 0.1% gelatin) and served as controls. Specimens in group B were intraperitoneally injected daily with 0.5 mg/50 g bw of salmon calcitonin (lot D 123180 B, Armour Pharmaceutical Co., USA) dissolved in vehicle. In all cases (control and treatment groups) the injection volume was 0.1 mL/50 g bw. CT was dissolved in vehicle; therefore, the control animals were also injected with vehicle. During the experimental period the animals were not fed.

Lizards in each group (n = 10) were sacrificed in batches 2 h after the last injection on the 1st, 3rd, 5th, 10th, and 15th day of treatment. Blood samples were taken into heparinized tubes via cardiac puncture at each experimental interval. Plasma was separated by centrifugation (3000 rpm) and analyzed for calcium (Sigma kit) and inorganic phosphate (Sigma kit) levels. After blood was collected the ultimobranchial gland (the region anterior to the heart) and PTG (near the carotid bifurcation) were removed from the lizards. The tissues were fixed in aqueous Bouin's solution. The fixed materials were routinely dehydrated in graded series of alcohols, cleared in xylene, and then embedded in paraffin. Serial 6- $\mu$ m sections were cut and stained with hematoxylin and eosin (H&E).

Nuclear (ultimobranchial and parathyroid cells) indices (maximum length and width) were determined with the aid of an ocular micrometer. Fifty nuclei were measured per animal. The nuclear volume was calculated as follows:

$$\text{volume} = 4/3 \pi ab^2$$

where 'a' is the major semi-axis and 'b' is the minor semi-axis.

All data are presented as the mean  $\pm$  SE of 10 specimens and Student's t test was used to determine statistical significance. For all studies the experimental group was compared to its time-specific control group. Two-way ANOVA in Minitab v.12.1 was used to detect significant differences by comparing 10 groups using 2 factors. A difference of  $P < 0.05$  was accepted as significant.

## Observations

Following treatment with calcitonin, the mean plasma calcium level in *C. versicolor* decreased on day

1 and this response progressed up to day 5 (Figure 1); thereafter, the level exhibited elevation, so that on day 15 a normal plasma calcium level was achieved (Figure 1). Two-way ANOVA indicated that the plasma calcium level differed significantly between treatments ( $F = 62.57, P < 0.001$ ) and between time intervals ( $F = 3.96, P < 0.007$ ).

There was no change in plasma phosphate levels on day 1 following calcitonin treatment. Progressive hypophosphatemia was observed from day 3 to 5 (Figure 2); thereafter, the level tended to increase, resulting in normophosphatemia on day 15 (Figure 2). Based on 2-way ANOVA, the plasma phosphate level differed significantly between treatments ( $F =$

$13.45, P < 0.001$ ) and between time intervals ( $F = 5.20, P < 0.001$ ).

The ultimobranchial gland in vehicle-injected *Calotes versicolor* specimens contained follicles (1 large follicle or a few small follicles), and cell cords or cell clumps (Figure 3). The follicles were lined by epithelium possessing simple cuboidal cells or pseudostratified columnar cells. The cells, which formed compact cell clumps, were similar; their nuclei were ovoid and contained dense chromatin material.

The ultimobranchial gland in the calcitonin-injected lizard did not exhibit any histological alterations up to day 5. Nuclear volume of the ultimobranchial cells decreased on day 10 and persisted until day 15 (Figure 4). Additionally, a few degenerating cells were observed following 15 days of calcitonin treatment (Figure 5). Comparison of

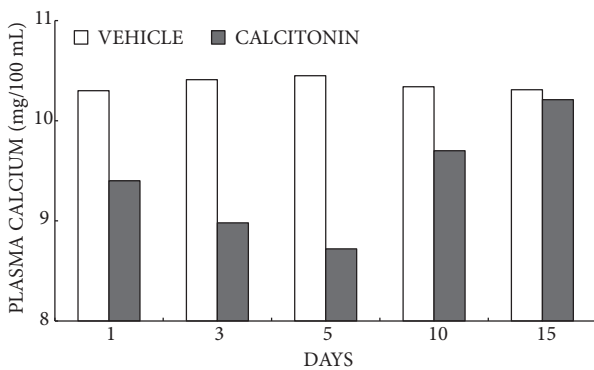


Figure 1. Plasma calcium levels of vehicle- or calcitonin-treated lizard. Values are mean  $\pm$  S.E. of 10 specimens. Values at day 1, day 3, and day 5 for calcitonin-treated lizards indicate significant differences ( $P < 0.05$ ) as compared with vehicle-injected animals.

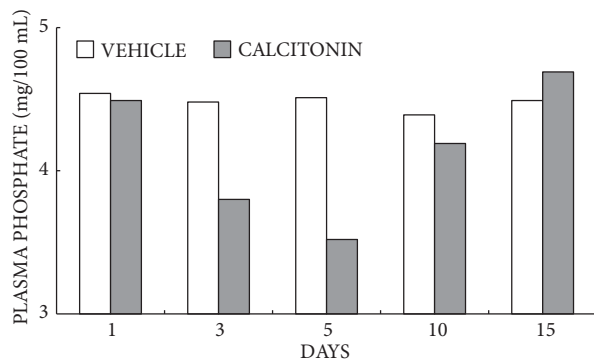


Figure 2. Plasma phosphate levels of vehicle- or calcitonin-treated lizard. Values are mean  $\pm$  S.E. of 10 specimens. Values at day 3 and day 5 for calcitonin-treated lizards indicate significant differences ( $P < 0.05$ ) as compared with vehicle-injected lizards.

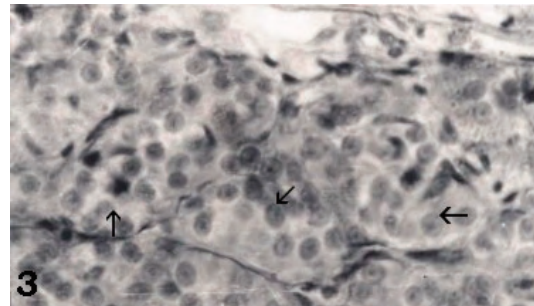


Figure 3. Ultimobranchial gland of vehicle-injected *Calotes versicolor*. Note the cells which are alike and arranged in cell cords or clumps (arrows). HE  $\times 200$ .

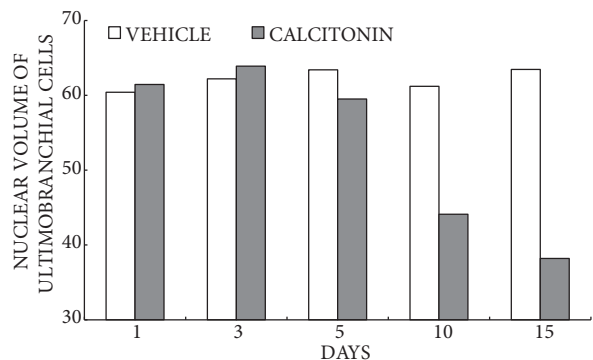


Figure 4. Nuclear volume of ultimobranchial cells ( $\mu\text{m}^3$ ) of vehicle- or calcitonin-treated *Calotes versicolor*. Values at day 10 and day 15 for calcitonin treated-lizards indicate significant differences ( $P < 0.05$ ) as compared with vehicle-injected animals.



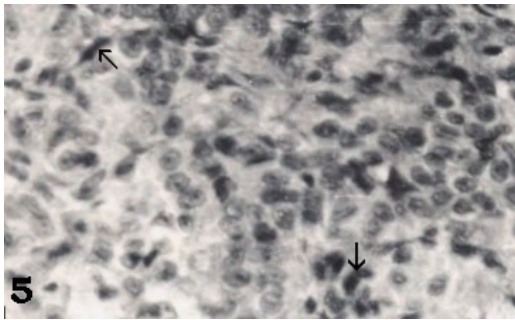


Figure 5. Degenerating cells (arrows) in the ultimobranchial gland of 15 days calcitonin-treated lizard. HE  $\times 200$ .

ultimobranchial cell nuclear volume data with 2-way ANOVA showed that the values differed significantly between treatments ( $F = 16.78$ ,  $P < 0.001$ ) and between time intervals ( $F = 5.58$ ,  $P < 0.001$ ).

In vehicle-injected *Calotes versicolor* specimens the cells of the PTGs were arranged in compact cords separated by connective tissue strands that contained blood vessels. The gland contained a single cell type, which was oval, rounded, or irregular in shape. These cells possessed an indistinct cell boundary (Figure 6). The parenchymal cells contained little cytoplasm and a large centrally located ovoid nucleus with 1 or more nucleoli (Figure 6).

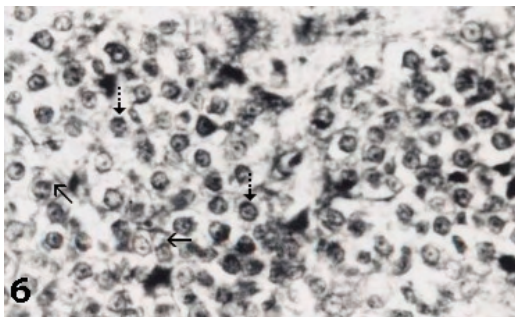


Figure 6. Parathyroid gland of vehicle-injected lizard. Note the single cell type arranged in cords and with indistinct cell boundaries. Mark scanty cytoplasm (arrows) and centrally located nucleus (broken arrows). HE  $\times 200$ .

The PTG in *C. versicolor* remained unaffected up to day 3 following calcitonin treatment. A progressive increase in the nuclear volume of parathyroid cells was observed from day 5 to the end of the experiment (day 15, Figure 7). The gland became compact on day 10 and day 15 (Figure 8). In addition, a few

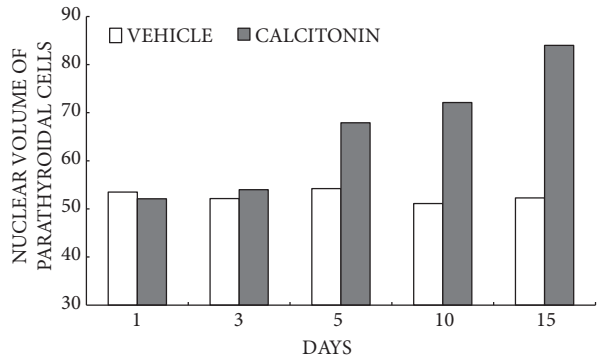


Figure 7. Nuclear volume of parathyroidal cells ( $\mu\text{m}^3$ ) of vehicle or calcitonin treated *Calotes versicolor*. Values at day 5, day 10, and day 15 for calcitonin treated lizards indicate significant differences ( $P < 0.05$ ) as compared with vehicle injected animals.

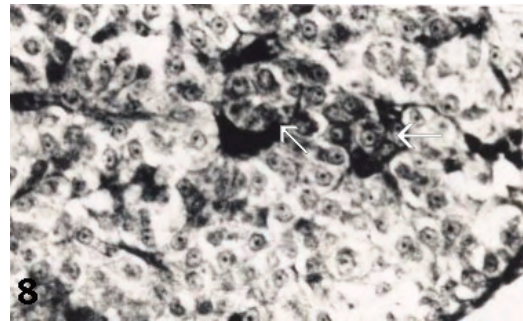


Figure 8. Parathyroid gland of 10 days calcitonin-treated *Calotes versicolor* showing compactness (white arrows). HE  $\times 200$ .

degenerating cells were observed after 15 days of calcitonin treatment (Figure 9). Parathyroid cell nuclear volume data subjected to 2-way ANOVA showed that it differed significantly between treatments ( $F = 44.29$ ,  $P < 0.001$ ) and between time intervals ( $F = 8.32$ ,  $P < 0.001$ ).

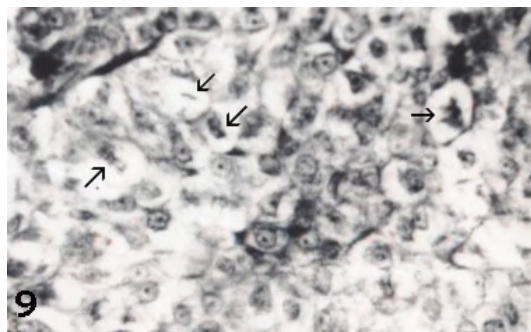


Figure 9. Degenerating cells (arrows) in parathyroid gland of 15 days calcitonin-treated lizard. HE  $\times 200$ .

## Discussion

The present study's results clearly show that calcitonin induced hypocalcemia and hypophosphatemia in *C. versicolor*. This is in agreement with reports by Kline (1981) for the green iguana and Srivastav and Rani (1989a) for *Natrix piscator*. In contrast, Clark (1971) and Dix et al. (1970) did not observe any effects of mammalian calcitonin on reptilian calcium regulation. Two explanations, i.e. the use of more biologically active salmon calcitonin and the employment of young specimens suggested by Kline (1981), and Srivastav and Rani (1989a), respectively, may account for the positive effects of calcitonin observed in the present study.

In the present study calcitonin-treated lizards exhibited normal plasma calcium levels on day 15. This may have been because of the occurrence of bone resorption due to the observed increase in activity of the PTG in *C. versicolor* in response to hypocalcemic challenge. The observed recovery of plasma calcium cannot be attributed to the increase in renal calcium reabsorption, as Clark and Laverty (1985) reported that reptiles appear to lack the ability to conserve renal calcium in response to parathyroid hormone.

Calcitonin induced hypophosphatemia in *C. versicolor*. This is in agreement with researchers that reported a similar effect of calcitonin in reptiles (Srivastav and Rani, 1989a, 1992) and amphibians (Srivastav and Rani, 1989b). Earlier, Clark (1971) reported a decrease in the serum phosphate level in normal garter snakes administered calcitonin, but the decrease was not significant. Later, Clark and Dantzler (1975) reported that as the samples were taken 4 h following calcitonin administration it is possible that a significant effect may have been missed. Additionally, they did not observe a significant change in the sham-operated snakes after calcitonin injection; however, this hormone caused serum phosphate values to decrease in the parathyroidectomized snakes.

In *C. versicolor* calcitonin-induced hypophosphatemia could not be attributed to hyperphosphaturia, as calcitonin has no effect on fractional excretion of phosphate in snakes (Clark and Dantzler, 1975). The observed hypophosphatemia in *C. versicolor* might have been due to inhibition of bone breakdown by calcitonin. The recovery of the plasma phosphate level in calcitonin-treated *C. versicolor* may have been due to possible bone resorption via increased activity of PTGs caused by prolonged hypocalcemic challenge. PTG hyperactivity, as observed in calcitonin-treated *C. versicolor*, is supported by studies on other vertebrates that describe a similar effect after calcitonin administration (Swarup et al., 1980; Srivastav and Swarup, 1982; Krishna and Swarup, 1985; Srivastav and Rani, 1988, 1989b, 1992; Srivastav et al., 1995). Anderson and Capen's (1976) results also support those of the present study, as they observed an increase in chief cell activity after maintaining *Iguana iguana* on a low calcium diet.

In the present study the ultimobranchial gland in *C. versicolor* exhibited inactivity following treatment with calcitonin, which is supported by Srivastav and Rani's (1992) results with snakes; they reported inactivity of the ultimobranchial gland after calcitonin administration. Moreover, other studies of vertebrates reported that calcitonin inhibited the release of calcitonin from calcitonin cells in mammals (Swarup et al., 1980; Srivastav and Swarup, 1982), and from the ultimobranchial gland in anurans (Krishna and Swarup, 1985; Srivastav and Rani, 1989b) and in fishes (Wendelaar Bonga, 1980; Srivastav et al., 1989c). Anderson and Capen's (1976) results support those of the present study, as they observed less ultimobranchial gland activity after inducing hypocalcemia in *Iguana iguana* by maintaining them on a low calcium diet.

## References

- Anderson, M.P. and Capen, C.C. 1976. Ultrastructural evaluation of parathyroid and ultimobranchial glands in iguanas with experimental nutritional osteodystrophy. *Gen. Comp. Endocrinol.* 30: 209-222.
- Clark, N.B. 1965. Experimental and histological studies of the parathyroid glands of freshwater turtles. *Gen. Comp. Endocrinol.* 5: 297-312.

- Clark, N.B. 1971. The ultimobranchial body of reptiles. *J. Exp. Zool.* 178: 115-124.
- Clark, N.B. and Dantzler, W.H. 1975. Renal tubular transport of calcium and phosphate in snakes. Role of calcitonin. *Gen. Comp. Endocrinol.* 26: 321-326.
- Clark, N.B. and Laverty, G. 1985. Role of parathyroid hormone in regulation of calcium in reptiles. In: *Current Trends in Comparative Endocrinology.* (eds. Lofts, B. and Holmes, W.N.) Hong Kong University Press, Hong Kong, pp. 843-845.
- Dacke, C.G. 1979. Calcium regulation in sub-mammalian vertebrates. Academic Press, London.
- Dix, M.W., Pang, P.K.T. and Clark, N.B. 1970. Lizard calcium metabolism: lack of effect of mammalian calcitonin on serum calcium or phosphate levels in normal and parathyroidectomized lizards *Anolis carolinensis*. *Gen. Comp. Endocrinol.* 14: 243-247.
- Hasan, N., Das, V.K. and Swarup, K. 1992. Effect of salmon calcitonin administration on serum calcium and inorganic phosphate levels of intact and ultimobranchialectomized freshwater snake, *Natrix piscator* (Schneider). *Nat. Acad. Sci. Letters* 15: 97-101.
- Kiebzak, G.M. and Minnick, J.E. 1982. Effects of calcitonin on electrolyte excretion in the lizard *Dipsosaurus dorsalis*. *Gen. Comp. Endocrinol.* 48: 232-238.
- Kline, L.W. 1981. A hypocalcemic response to synthetic salmon calcitonin in the green iguana, *Iguana iguana*. *Gen. Comp. Endocrinol.* 44: 476-479.
- Krishna, L. and Swarup, K. 1985. Response of parathyroid gland, ultimobranchial body, paravertebral lime-sacs and serum calcium level to salmon calcitonin administration in *Rana cyanophlyctis* (Anura: Amphibia). *Herpetologica* 41: 65-70.
- Srivastav, Ajai K. and Rani, L. 1988. Mammalian calcitonin cells: Retrospect and prospect. *Biological Struct. Morphogen.* 1: 117-123.
- Srivastav, Ajai K. and Rani, L. 1989a. Serum calcium and inorganic phosphorus level of the freshwater snake, *Sinonatrix piscator* (formerly *Natrix piscator*) in response to calcitonin treatment. *Can. J. Zool.* 67: 1335-1337.
- Srivastav, Ajai K. and Rani, L. 1989b. Influence of calcitonin administration on serum calcium and inorganic phosphate of the frog, *Rana tigrina*. *Gen. Comp. Endocrinol.* 74: 14-17.
- Srivastav, Ajai K. and Rani, L. 1992. Effects of calcitonin administration on the ultimobranchial body and parathyroid glands of the freshwater snake, *Natrix piscator*. *European Arch. Biol.* 103: 181-185.
- Srivastav, Ajai K. and Swarup, K. 1982. Effect of calcitonin on calcitonin cells, parathyroid glands and serum electrolytes in the house shrew, *Suncus murinus*. *Acta anatomica* 114: 81-87.
- Srivastav, Ajai K., Das, V.K., Srivastav, S.K., Sasayama, Y. and Suzuki, N. 1998. Morphological and functional aspects of reptilian ultimobranchial gland. *Anat. Histol. Embryol.* 27: 359-364.
- Srivastav, Ajai K., Sasayama, Y. and Suzuki, N. 1995. Morphology and physiological significance of parathyroid glands in reptilia. *Micro. Res. Tech.* 32: 91-103.
- Srivastav, Ajai K., Yadav Seema Srivastav, S.K. and Suzuki, N. 2008. The ultimobranchial gland in poikilotherms: Morphological and functional aspects. In: "Experimental Endocrinology and Reproductive Biology" (Eds. C. Haldar, M. Singaravel, S.R. Pandi-Perumal and D.P. Cardinali), Science Publishers, Enfield, NH, USA, pp. 269-296.
- Srivastav, Ajai K., Srivastav, S.P., Srivastav, S.K. and Swarup, K. 1986. Calcitonin effects on serum calcium levels of the freshwater snake, *Natrix piscator*. *Gen. Comp. Endocrinol.* 61: 436-437.
- Srivastav, S.P., Swarup, K., Singh, S. and Srivastav, Ajai K. 1989c. Effects of calcitonin administration on ultimobranchial gland, Stannius corpuscles and prolactin cells in male catfish, *Clarias batrachus*. *Arch. Biol.* 100: 385-392.
- Swarup, K., Tewari, N.P. and Srivastav, Ajai K. 1980. Response of calcitonin cells, parathyroid glands and bone to prolonged calcitonin administration in the Indian palm squirrel, *Funambulus pennanti* (Wroughton). *Acta Anatomica* 106: 180-191.
- Wendelaar Bonga, S.E. 1980. Effect of synthetic salmon calcitonin and low ambient calcium on plasma calcium, ultimobranchial cells, Stannius bodies and prolactin cells in the teleost *Gasterosteus aculeatus*. *Gen. Comp. Endocrinol.* 40: 99-108.
- Wendelaar Bonga, S.E.W. and Pang, P.K.T. 1991. Control of calcium regulating hormones in the vertebrates: parathyroid hormone, calcitonin, prolactin, and stanniocalcin. *International Review Cytology* 128: 139-213.