

1-1-2013

## First detection and molecular identification of *Babesia gibsoni* in two dogs from the Aydın Province of Turkey

NURAN AYSUL

KEREM URAL

BÜLENT ULUTAŞ

HASAN EREN

TÜLİN KARAGENÇ

Follow this and additional works at: <https://journals.tubitak.gov.tr/veterinary>



Part of the [Animal Sciences Commons](#), and the [Veterinary Medicine Commons](#)

---

### Recommended Citation

AYSUL, NURAN; URAL, KEREM; ULUTAŞ, BÜLENT; EREN, HASAN; and KARAGENÇ, TÜLİN (2013) "First detection and molecular identification of *Babesia gibsoni* in two dogs from the Aydın Province of Turkey," *Turkish Journal of Veterinary & Animal Sciences*: Vol. 37: No. 2, Article 17. <https://doi.org/10.3906/vet-1201-45>

Available at: <https://journals.tubitak.gov.tr/veterinary/vol37/iss2/17>

This Article is brought to you for free and open access by TÜBİTAK Academic Journals. It has been accepted for inclusion in Turkish Journal of Veterinary & Animal Sciences by an authorized editor of TÜBİTAK Academic Journals. For more information, please contact [academic.publications@tubitak.gov.tr](mailto:academic.publications@tubitak.gov.tr).

## First detection and molecular identification of *Babesia gibsoni* in two dogs from the Aydın Province of Turkey

Nuran AYSUL<sup>1</sup>, Kerem URAL<sup>2</sup>, Bülent ULUTAŞ<sup>2</sup>, Hasan EREN<sup>1</sup>, Tülin KARAGENÇ<sup>1\*</sup>

<sup>1</sup>Department of Parasitology, Faculty of Veterinary Medicine, Adnan Menderes University, Aydın, Turkey

<sup>2</sup>Department of Internal Medicine, Faculty of Veterinary Medicine, Adnan Menderes University, Aydın, Turkey

Received: 27.01.2012 • Accepted: 15.05.2012 • Published Online: 15.03.2013 • Printed: 15.04.2013

**Abstract:** Small (1–3 µm in diameter, ring, oval, or comma shaped) piroplasms suggestive of *Babesia* spp. were observed upon microscopic examination of Giemsa-stained peripheral blood smears from a 3.5-year-old American Pit Bull Terrier with clinical signs of pyrexia, weakness, mucous membrane pallor, and depression living in Aydın, Turkey, in February, 2009. To confirm the presence and to identify the species of *Babesia* spp., a polymerase chain reaction (PCR) technique was performed using primers amplifying a 670 bp fragment of the 18S rRNA gene of *Babesia gibsoni* and the PCR products were analyzed by sequencing. The nucleotide sequence was compared to the sequences available in GenBank using the nucleotide Basic Local Alignment Search Tool program. The results indicated a 99% similarity with sequences of *Babesia gibsoni*. A 2-year-old American Staffordshire Terrier with no signs of any diseases was also confirmed to be infected with *B. gibsoni* using the same methods. To the best of our knowledge, this is the first report demonstrating the presence of *B. gibsoni* in Aydın, Turkey.

**Key words:** *Babesia gibsoni*, dog, PCR, Turkey

Canine babesiosis is a tick-borne disease caused by protozoal parasites including large *Babesia* species such as *Babesia canis*, *B. vogeli*, *B. rossi*, and small *Babesia* species, namely *Babesia gibsoni*, *B. conradae*, and *B. microti*-like species (*Theileria annae* or “Spanish dog isolate”) (1). These parasites infect the erythrocytes of dogs, leading to hemolytic anemia. Infection with *B. gibsoni* is known to cause more severe clinical signs than infection with large *Babesia* spp. and may result in multiple organ dysfunction syndrome (2). Large *Babesia* species can be easily differentiated microscopically from *B. gibsoni* as the piroplasms of *Babesia canis*, *B. vogeli*, and *B. rossi* are larger (2–5 µm) than that of *B. gibsoni* (1–3 µm) (1,3).

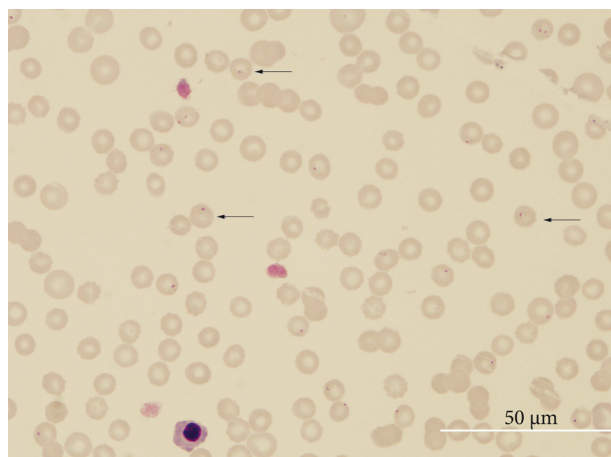
The diagnosis of babesiosis is carried out through the determination of *Babesia* spp. in thin-film blood smears stained with Giemsa. However, morphology alone cannot be used for species differentiation. This arises from the fact that *B. gibsoni* is pleomorphic and possesses extensive similarities with other small piroplasms of dogs including *Theileria equi* (4), *B. microti*-like species (5), and *B. conradae* (6). Furthermore, the number of *Babesia* species that can be characterized in dogs is on the rise as a consequence of new developments in molecular methods (1).

*Babesia gibsoni* has been reported in various regions of the world (7–9). To the best of our knowledge, however,

there is no report in the literature demonstrating the infection of dogs with *B. gibsoni* in Turkey. *Rhipicephalus sanguineus* and *Haemaphysalis bispinosa* are responsible for the transmission of the parasite (9). While *R. sanguineus* is a common tick species in Turkey (10), there are no data demonstrating the existence of *H. bispinosa*. Numerous cases of babesiosis caused by *B. gibsoni* in fighting dog breeds such as the American Pitt Bull Terrier and American Staffordshire Terrier have been reported from various countries (8). It is suggested on the basis of the occurrence of babesiosis, mainly in fighting dogs, that the route of transmission of the parasite is through blood as a consequence of bleeding during fighting. We report in the present study for the first time the presence of *B. gibsoni* infection in 2 fighting dogs in Aydın, Turkey, by microscopic examination combined with polymerase chain reaction (PCR) and sequence analysis.

A 3.5-year-old male American Pit Bull Terrier was referred to the Faculty of Veterinary Medicine at Adnan Menderes University in February, 2009, with clinical signs including pyrexia, weakness, mucous membrane pallor, and depression. The dog was born in Aydın and had not been taken to any other country. Anemia and lymphadenopathy were detected upon clinical examination. The dog was allowed to roam outside frequently and had a history of

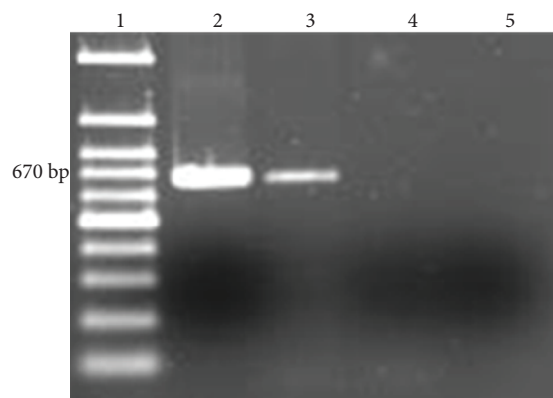
\* Correspondence: [tulinkaragenc@yahoo.com](mailto:tulinkaragenc@yahoo.com)



**Figure 1.** Ring, oval, and comma shaped small *Babesia* parasites (arrows) detected in thin blood smears.

fighting with stray dogs 3 weeks before admission to the clinic. According to the owner, the dog was routinely vaccinated and treated for external and internal parasites on a regular basis. No ticks were found during the physical examination. However, splenomegaly was evident on ultrasonographic examination. Hematological analysis revealed microcytic-hypochromic anemia (red blood count,  $1.57 \times 10^6/\mu\text{L}$ ; mean cell volume (PCV), 39.2 fL; mean corpuscular hemoglobin concentration, 29.21%; hemoglobin, 6.4 g/dL; and packed cell volume, 21.0%), thrombocytopenia ( $75 \times 10^9/\text{L}$ ), and elevated alanine transaminase and aspartate aminotransferase levels (98 and 116 IU/L, respectively) in association with hepatic hypoxia. These parameters suggested that the dog might have blood parasites, hemolytic anemia, and/or other relevant infectious diseases. In an attempt to distinguish between these possibilities, microscopic examination of Giemsa-stained thin blood smears prepared from the ear margin was carried out. Ring shaped, oval, and comma-like organisms, about 1–3  $\mu\text{m}$  in diameter, were detected in the erythrocytes (Figure 1). The degree of parasitemia, calculated as the percentage of infected red blood cells by counting 1000 red blood cells, was 5.4%. On the basis of the size of the intracellular parasites observed in this case, the possibility that the dog might have been infected with small *Babesia* spp., especially with *B. gibsoni*, was considered. The fact that *B. gibsoni* cannot be distinguished from other canine small babesial isolates by microscopy prompted us to use PCR followed by sequence analysis for a definitive diagnosis.

DNA from ethylenediaminetetraacetic acid-treated blood (300  $\mu\text{L}$ ) was extracted using the Wizard<sup>®</sup> Genomic DNA purification Kit (Promega Corporation, Madison, WI, USA) according to the manufacturer's instructions. A primer set including Gib599F (5'-CTC-GGC-TAC-TTG-CCT-TGT-C-3') and Gib1270R (5'-GCC-GAA-ACT-GAA-ATA-ACG-GC-3') (Thermo Electron GmbH,



**Figure 2.** Amplification of the small 18S rRNA gene region of *B. gibsoni* with the primers Gib599 and Gib1270 from an infected dog in Aydın, Turkey. 1: 100 bp molecular marker, 2: clinically sick dog (American Pit Bull Terrier), 3: the second dog (American Staffordshire Terrier), 4: negative dog sample, and 5: negative control (water). The PCR products were run on 1.5% agarose gel and stained with ethidium bromide.

Germany) was used to amplify a 670 bp fragment of the 18S rRNA gene region specific to *B. gibsoni* (11). The PCR mix consisted of 12.5 pmol of each primer, 100  $\mu\text{M}$  of each dNTP (Roche Diagnostics GmbH, Roche Applied Science, Germany), 1X PCR reaction buffer, 1.25 U Taq DNA polymerase (Roche Diagnostics GmbH) and 5  $\mu\text{L}$  DNA in a final volume of 25  $\mu\text{L}$ . The cycling conditions were as follows: 95 °C for 5 min, followed by 35 cycles at 95 °C for 30 s, 55 °C for 30 s, 72 °C for 90 s, and a final extension step of 72 °C for 10 min. A negative sample control (canine blood DNA only) and a negative DNA control (Milli-Q water in a substitute of DNA) were included in the PCR reaction. The PCR products were run on 1.5% agarose gel and stained with ethidium bromide. The size of the amplified PCR product was 670 bp (Figure 2). To confirm the results of the PCR, the PCR product was sent to İontek (İstanbul, Turkey) for sequence analysis. The nucleotide sequence was compared with available sequences in GenBank using the nucleotide Basic Local Alignment Search Tool program. The analysis indicated that there is a 99% similarity with various sequences of the *B. gibsoni* 18S rRNA gene deposited in GenBank (Accession numbers: AB478330.1, AB478328.1, FJ769388.1, EU084679.1, etc.). This finding demonstrated that the dog was infected with *B. gibsoni*. The sequence of the PCR product was then submitted to the GenBank database (accession number: JN562745).

Once the dog was diagnosed as being infected with *B. gibsoni*, the dog was treated with imidocarb dipropionate (2.5 mg/kg single dose, intramuscularly) and oxytetracycline (25 mg/kg twice a day, subcutaneously for 14 days). A blood transfusion was also performed on the first day of the treatment. The PCV was monitored and showed elevation during the course of the treatment

(the PCV being 32% on day 7 after the treatment). Fifteen days after the treatment, the dog appeared healthy with no clinical signs of anemia. The well-being of the dog was confirmed with the owner 2 months after the treatment.

In addition to the dog that is discussed above, a 2-year-old male American Staffordshire Terrier, kept by the same owner, with previous involvement in dog fighting, was also examined. Blood samples were taken considering the possibility that this dog also might be infected with *B. gibsoni*. No parasites were detected upon microscopic examination of Giemsa-stained blood smears. However, PCR revealed that the dog was infected with *B. gibsoni* (Figure 2). The kennel housing these 2 dogs was examined for the presence of ticks, but no ticks were found.

Blood samples were taken from both dogs 5 months after the initial examination, to be used in microscopic examination and PCR. Although no piroplasms were detected by microscopic examination, the dogs were found to be positive by PCR.

The present study describes the infection of 2 dogs with *B. gibsoni* in Aydın, a city in western Turkey. Although there are a few reports indicating the existence of *B. vogeli* in dogs in Turkey (12–14), to the best of our knowledge, this is the first report demonstrating the existence of *B. gibsoni* in Turkey.

In recent years, there has been an increase in the number of reports demonstrating the presence of *B. gibsoni* infection in dogs in both Europe and Asia (8,9,11). Most of the confirmed cases of *B. gibsoni* infection were found among fighting dog breeds, such as Tosa, American Pit Bull Terrier, and American Staffordshire Terrier (1,2,15,16). The cases reported in the present study are in agreement with these observations. Two hypotheses can be put forward to explain these observations. First, these particular breeds might be genetically susceptible to the disease, and second, environmental factors might lead to high exposure to vector ticks (9).

It is generally accepted that *R. sanguineus* is the tick vector for *B. gibsoni* (17). *R. sanguineus* is a common tick species in Turkey (10). Recent studies indicate that *R. sanguineus* does also exist in the Aydın region (18). Nevertheless, to date, there is no experimental evidence demonstrating the transmission of the parasite through this tick species. It might be important to note in this context that no ticks were detected on the animals. This could be either due to the absence of ticks in the kennel or the fact that the dogs received acaricides on a regular

base. This raises the possibility that blood exchange during fighting may be involved in the transmission of the parasite through bite wounds, as suggested previously (1,2,15,19). The observation indicating that the dogs confirmed to be positive for *B. gibsoni* have a lower rate of tick exposure along with a history of dog fighting support this hypothesis. However, it should be pointed out that the present study provides no evidence as for the mode of transmission of the parasite.

Common clinical and pathological findings including anemia, lethargy, anorexia, marked splenomegaly, and thrombocytopenia were observed in one of the cases described in the present study. This is in accordance with previous studies (9,16,21). The administration of imidocarb dipropionate and oxytetracycline along with a blood transfusion resulted in the successful treatment of the clinical signs in the dog showing symptoms of the disease. On the other hand, the dog was found to be positive by PCR 5 months following the treatment. This would suggest that the antibabesial drugs cannot eliminate the parasite, as reported previously (21,22). The observation that the dogs were still positive for *B. gibsoni* 5 months after the initial examination indicates that they have become carriers of the parasite. It should be noted that the dogs becoming carriers of *B. gibsoni* could serve as a potential source of the infection for the uninfected ticks. Further investigations are needed to demonstrate whether or not this is the case. Tick bites are reported to be the most common mode of transmission in Southeast Asia (20). It appears from these observations that the main mode of transmission varies among different regions of the world. In order to determine the mode of transmission, the prevalence of the disease should be compared between dogs with and without a history of dog fighting.

Taken together, we provide in the present study microscopic and molecular evidence of *B. gibsoni* infection in 2 dogs with a history of dog fighting. On the basis of previously reported cases of babesiosis caused by *B. gibsoni*, various hypotheses could be put forward as to the mode of the transmission of the parasite, i.e. by the tick bites or dog to dog contact. However, it should be pointed out that only 2 dogs were found to be positive in the present report, which makes it difficult to draw any conclusions as to the source of the infection. Further studies using a higher number of dogs should be conducted to determine the range, prevalence, route of transmission, and clinical impact of *Babesia* species infecting dogs in Turkey.

## References

1. Solano-Gallego, L., Baneth, G.: Babesiosis in dogs and cats—expanding parasitological and clinical spectra. *Vet. Parasitol.*, 2011; 181: 48–60.
2. Miyama, T., Sakata, Y., Shimada, Y., Ogino, S., Watanabe, M., Itamoto, K., Okuda, M., Verdida, R.A., Xuan, X., Nagasawa, H., Inokuma, H.J.: Epidemiological survey of *Babesia gibsoni* infection in dogs in eastern Japan. *Vet. Med. Sci.*, 2005; 67: 467–471.

3. Kuttler, K.L.: World-wide impact of babesiosis. In: Ristic, M., Ed. *Babesiosis of Domestic Animals and Man*. CRC Press, Boca Raton, FL, 1988; 1–22.
4. Purnell, R.E.: Babesiosis in various hosts. In: Ristic, M., Kreier, J.P., Eds. *Babesiosis*. Academic Press, New York. 1981; 25–63.
5. Conrad, P.A., Thomford, J.W., Marsh, A., Telford S.R. 3rd, Anderson, J.F., Spielman, A., Sabin, E.A., Yamane, I., Persing, D.H.: Ribosomal DNA probe for differentiation of *Babesia microti* and *B. gibsoni* isolates. *J. Clin. Microbiol.*, 1992; 30: 1210–1215.
6. Kjemtrup, A.M., Wainwright, K., Miller, M., Penzhorn, B.L., Ramon, A., Carreno, A.R.: *Babesia conradae*, sp. nov., a small canine *Babesia* identified in California. *Vet. Parasitol.*, 2006; 138: 103–111.
7. García, A.T.: Piropasma infection in dogs in northern Spain. *Vet. Parasitol.*, 2006; 138: 97–102.
8. Jefferies, R., Ryan, U.M., Jardin, J., Broughton, D.K., Robertson, I.D., Irwin, P.J.: Blood, Bull terriers and babesiosis: further evidence for direct transmission of *Babesia gibsoni* in dogs. *Aust. Vet. J.*, 2007; 85: 459–463.
9. Taboada, J., Lobetti, R.: Babesiosis. In: Greene, C.E., Ed. *Infectious Diseases of the Dog and Cat*. Saunders Elsevier, Philadelphia. 2006; 722.
10. Aydin, L., Bakirci, S.: Geographical distribution of ticks in Turkey. *Parasitol. Res.*, 2007; 101: 163–166.
11. Inokuma, H., Yoshizaki, Y., Matsumoto, K., Okuda, M., Onishi, T., Nakagome, K., Kosugi, R., Hirakawa, M.: Molecular survey of *Babesia* infection in dogs in Okinawa, Japan. *Vet. Parasitol.*, 2004; 121: 341–346.
12. Aysul, N.: Comparison of microscopic and PCR-RLB findings in detection of *Babesia* species of dogs in İstanbul. PhD Dissertation. İstanbul University Graduate School of Health Sciences, İstanbul, Turkey. 2006.
13. Gülanber, A., Gorenflot, A., Schettters, T.P.M., Carcy, B.: First molecular diagnosis of *Babesia vogeli* in domestic dogs from Turkey. *Vet. Parasitol.*, 2006; 139: 224–230.
14. Kirli, G.: Prevalence of canine babesiosis in Aegean Region of Turkey. MS Dissertation. Adnan Menderes University Graduate School of Health Sciences, Aydın, Turkey. 2006.
15. Ikadai, H., Tanaka, H., Shibahara, N., Matsuu, A., Uechi, M., Itoh, N., Oshiro, S., Kudo, N., Igarashi, I., Oyamada, T.: Molecular evidence of infections with *Babesia gibsoni* parasites in Japan and evaluation of the diagnostic potential of a loop-mediated isothermal amplification method. *J. Clin. Microbiol.*, 2004; 42: 2465–2469.
16. Trotta, M., Carli, E., Novari, G., Furlanello, T., Solano-Gallego, L.: Clinicopathological findings, molecular detection and characterization of *Babesia gibsoni* infection in a sick dog from Italy. *Vet. Parasitol.*, 2009; 165: 318–322.
17. Yamane, I., Gardner, I.A., Telford, III S.R., Elward, T., Hair, J.A., Conrad, P.A.: Vector competence of *Rhipicephalus sanguineus* and *Dermacentor variabilis* for American isolates of *Babesia gibsoni*. *Exp. Appl. Acarol.*, 1993; 17: 913–919.
18. Bakirci, S.: Distribution of tick species on cattle in the Western Anatolia, PhD Dissertation. Uludağ University Graduate School of Health Sciences, Bursa, Turkey. 2009.
19. Yeagley, T.J., Reichard, M.V., Hempstead, J.E., Allen, K.E., Parsons, L.M., White, M.A., Little, S.E., Meinkoth, J.H.: Detection of *Babesia gibsoni* and the canine small *Babesia* ‘Spanish isolate’ in blood samples obtained from dogs confiscated from dogfighting operations. *J. Am. Vet. Med. Assoc.*, 2009; 235: 535–539.
20. Konishi, K., Sakata, Y., Miyazaki, N., Jia, H., Goo, Y.K., Xuan, X., Inokuma, H.: Epidemiological survey of *Babesia gibsoni* infection in dogs in Japan by enzyme-linked immunosorbent assay using *B. gibsoni* thrombospondin-related adhesive protein antigen. *Vet. Parasitol.*, 2008; 155: 204–208.
21. Jefferies, R., Ryan, U.M., Jardine, J., Robertson, I.D., Irwin, P.J.: *Babesia gibsoni*: detection during experimental infections, and after combined atovaquone and azithromycin therapy. *Exp. Parasitol.*, 2007; 117: 115–123.
22. Birkenheuer, A.J., Levy, M.G., Breitschwerdt, E.B.: Efficacy of combined atovaquone and azithromycin for therapy of chronic *Babesia gibsoni* (Asian genotype) infections in dogs. *J. Vet. Intern. Med.*, 2004; 18: 494–498.