

1-1-2018

The diagnostic value of elastography score and strain index for the evaluation of thyroidmicronodules

ERMAN ÇAKAL

MELİA KARAKÖSE

İLKNUR ÖZTÜRK ÜNSAL

MUSTAFA ŞAHİN

BEKİR UÇAN

See next page for additional authors

Follow this and additional works at: <https://journals.tubitak.gov.tr/medical>

 Part of the [Medical Sciences Commons](#)

Recommended Citation

ÇAKAL, ERMAN; KARAKÖSE, MELİA; ÜNSAL, İLKNUR ÖZTÜRK; ŞAHİN, MUSTAFA; UÇAN, BEKİR; and ÖZBEK, MUSTAFA (2018) "The diagnostic value of elastography score and strain index for the evaluation of thyroidmicronodules," *Turkish Journal of Medical Sciences*: Vol. 48: No. 5, Article 23. <https://doi.org/10.3906/sag-1802-195>

Available at: <https://journals.tubitak.gov.tr/medical/vol48/iss5/23>

This Article is brought to you for free and open access by TÜBİTAK Academic Journals. It has been accepted for inclusion in Turkish Journal of Medical Sciences by an authorized editor of TÜBİTAK Academic Journals. For more information, please contact academic.publications@tubitak.gov.tr.

The diagnostic value of elastography score and strain index for the evaluation of thyroidmicronodules

Authors

ERMAN AKAL, MELIA KARAKÖSE, İLKNUR ÖZTÜRK ÜNSAL, MUSTAFA ŞAHİN, BEKİR UÇAN, and MUSTAFA ÖZBEK

The diagnostic value of elastography score and strain index for the evaluation of thyroid micronodules

Erman ÇAKAL¹, Melia KARAKÖSE^{1*}, İlknur ÖZTÜRK ÜNSAL¹, Mustafa ŞAHİN², Bekir UÇAN¹, Mustafa ÖZBEK¹

¹Department of Endocrinology and Metabolism, Dışkapı Yıldırım Beyazıt Training and Research Hospital, Ankara, Turkey

²Department of Endocrinology and Metabolism, School of Medicine, Ankara University Ankara, Turkey

Received: 26.02.2018 • Accepted/Published Online: 23.07.2018 • Final Version: 31.10.2018

Background/aim: In the general population, the frequency of thyroid micronodules is increasing, and the prevalence of malignancy is higher for such nodules. Ultrasonography findings of these nodules are neither specific nor sensitive. The aim of this study was to investigate the diagnostic value of elastography in patients with thyroid micronodules.

Materials and methods: A total of 224 patients with thyroid micronodules were recruited in this prospective study. All patients underwent a thyroid fine-needle aspiration biopsy. Elastography scores (ESs) and strain indexes (SIs) were measured with real-time ultrasound elastography.

Results: Malignant micronodules had higher ES and SI values than those of benign micronodules ($P < 0.001$). When ES was used to diagnose malignancy, scores of >3 showed sensitivity of 79.4% and specificity of 98.1%. The area under the curve (AUC) for ES was 0.888 ($P < 0.001$). The optimal SI cutoff value that differentiated benign from malignant micronodules was 3.06 (98% sensitivity; 91% specificity). The AUC for SI was 0.970 ($P < 0.001$).

Conclusions: ES and SI are beneficial markers for detecting malignant thyroid micronodules. We showed that SI is better than ES when assessing the malignancy of thyroid micronodules.

Key words: Thyroid micronodules, malignancy, elastography, strain index

1. Introduction

Thyroid nodules are frequently discovered in clinical practice, either during physical examination or incidentally during imaging procedures. In the general population, up to 50%–60% of healthy individuals have thyroid nodules (1). The clinical significance of the evaluation of the thyroid nodule is mainly related to the need for exclusion of thyroid cancer, which accounts for 4%–6.5% of thyroid nodule cases and is usually independent of the nodule size (2,3). Fine-needle aspiration (FNA) is considered the most accurate method for distinguishing benign thyroid nodules from malignant ones (4). It is not appropriate to evaluate all thyroid nodules with FNA because of the high prevalence of such nodules.

Thyroid ultrasonography (US) is a valuable imaging method widely used for the evaluation of thyroid nodules. Although it is an inexpensive and noninvasive procedure, it provides important information about the nodules, such as the dimensions and parenchymal changes and structure. Thyroid US features that have been found

to be independent risk factors for malignancy include irregular margins, incomplete halo, hypoechoogenicity, microcalcifications, taller-than-wide shape, and central vascularity (5). Nevertheless, the specificity, sensitivity, positive predictive value (PPV), and negative predictive value (NPV) of US is extremely variable across studies; none of the abovementioned features have both high specificity and high sensitivity (6,7).

Harder nodules generally tend to be malignant. However, conventional US does not provide information about the hardness of a nodule; therefore, elastography, which is a noninvasive method to obtain information about tissue stiffness, has been developed. Elastography scores (ESs) and strain indexes (SIs) of malignant nodules are higher than those of benign thyroid nodules (8,9). It has been reported that elastography is useful for the investigation of malignancy and may reduce the number of unnecessary FNAs (10). ES and SI have been used to differentiate benign and malignant thyroid nodules in previous studies (11,12). However, their diagnostic value

* Correspondence: meliakarakose@yahoo.com

for thyroid micronodules has been assessed in only a few reports (13,14). Therefore, we aimed to investigate the diagnostic value of ES and SI for identifying the characteristics of thyroid micronodules.

2. Materials and methods

This prospective study was conducted between January 2016 and March 2017 in our hospital at the Department of Endocrinology and Metabolism outpatient clinic. The patients who had nodules with diameter of ≤ 10 mm determined on thyroid US at our hospital were enrolled in the study. There were 26 males and 198 females aged 21–74 years. Thyroid fine-needle aspiration biopsy (FNAB) were performed for all patients to investigate the diagnostic values of ES and SI. They were operated on if their cytology results confirmed or suspected malignancy according to the Bethesda system (BS) (15). The study protocol was approved by the ethics committee of our hospital, and written informed consent was obtained from all the participants.

Thyroid US and elastography were performed using high-resolution B-mode gray-scale US, power Doppler US, and real-time US elastography (Preirus HV with 13-MHz linear transducer). Only one operator performed all the measurements. The classical gray-scale features of the nodules were evaluated. Color flow Doppler pattern was classified as type 1 in the absence of blood flow, type 2 in the presence of perinodular blood flow, and type 3 in the presence of a marked intranodular blood flow (16). ES measurements were classified using the Itoh elasticity score scale (17).

Thyroid-stimulating hormone (TSH) and free T4 (fT4) levels were measured using a chemiluminescent microparticle immunoassay (Abbott, Architect i2000, Abbott Laboratories Diagnostics Division, USA). The lower and upper limits were as follows: fT4: 0.58–1.60 ng/dL; TSH: 0.38–5.33 μ U/mL All the patients were euthyroid, and serum calcitonin was undetectable.

2.1. Statistical analysis

Statistical analysis was performed using SPSS 17 (SPSS Inc., Chicago, IL, USA). All the measurement data were reported as the mean \pm standard deviation, and their differences were evaluated with the independent sample t-test. Sensitivity, specificity, PPV, and NPV were calculated from the cross tables. The associations between the categorical variables and malignancy, ES, or SI were evaluated using the Pearson chi-square test or Spearman rank test. Receiver operating characteristic (ROC) curves were analyzed, and the diagnostic performance of different variables was expressed as the area under the curve (AUC). $P < 0.05$ was considered statistically significant.

3. Results

The study included 198 (88.4%) females and 26 (11.6%) males with solitary thyroid nodules sized ≤ 10 mm in diameter on US. The mean age of the patients was 46.5 ± 12.2 years. Each patient had only one nodule, and 117 (52.2%) nodules were on the right, 92 (41.1%) on the left, and 15 (6.7%) in the isthmus. FNAB results of our study showed that 44 (19.6%) nodules were malignant, 19 (8.5%) were suspicious for malignancy, 43 (19.2%) had atypia of undetermined significance (AUS), 108 (48.2%) were benign, and 10 (4.5%) had nondiagnostic (ND) cytology.

ES was 1 in 17 cases and 2 in 63, all of which were nonmalignant; 3 in 74 cases, four of which were suspected of malignancy and nine of which were confirmed to be malignant; 4 in 60 cases, 14 of which were suspected of malignancy and 26 of which were confirmed to be malignant; and 5 in 10 cases, one of which was suspected of malignancy and nine of which were confirmed to be malignant (Table 1). The patients whose FNAB results confirmed or suspected malignancy underwent surgery. According to the histopathological results, all of them were diagnosed with papillary thyroid microcarcinoma.

Of the 63 nodules that were histopathologically diagnosed as papillary microcarcinoma, 35 (55.6%)

Table 1. Distribution of the types of micronodules according to the elastosonography scores.

Score	Benign (%)	ND (%)	AUS (%)	Suspicious for malignancy (%)	Malignant (%)
1	16 (14.8)	0 (0.0)	1 (2.3)	0 (0.0)	0 (0.0)
2	47 (43.5)	5 (50.0)	11 (25.6)	0 (0.0)	0 (0.0)
3	43 (39.8)	3 (30.0)	15 (34.9)	4 (21.0)	9 (20.5)
4	2 (1.9)	2 (20.0)	16 (37.2)	14 (73.7)	26 (59.0)
5	0 (0.0)	0 (0.0)	0 (0.0)	1 (5.3)	9 (20.5)
Total	108 (100.0)	10 (100.0)	43 (100.0)	19 (100.0)	43 (100.0)

ND: Nondiagnostic. AUS: atypia of undetermined significance.

were hypoechoic, 34 had (54%) microcalcification, 35 had (55.6%) irregular margin, and only one had halo (1.6%). Doppler US showed that 10 of the 63 malignant nodules (15.9%) had type 3 vascularization pattern; there was no significant difference in the vascularity pattern between benign and malignant micronodules ($P > 0.05$). However, irregular margin, absence of peripheral halo, hypoechogenicity, and microcalcification were significantly different between the two groups ($P < 0.001$). There were no significant differences in the TSH levels between benign and malignant micronodules (1.8 ± 1.3 and 2.2 ± 1.2 , respectively; $P = 0.058$).

There were significant differences between the mean ES (2.3 ± 0.7 and 3.9 ± 0.6 , respectively; $P < 0.001$) and SI (1.8 ± 0.9 and 4.8 ± 1.5 , respectively; $P < 0.001$) for benign and malignant micronodules. We found that 52 micronodules had ES of >3 , of which 50 (96.1%) were malignant. When we used ES to diagnose malignancy of thyroid micronodules, the AUC of the ROC curve was 0.888 (95% confidence interval: 0.826–0.950; $P < 0.001$; Table 2). ES represented malignancy; sensitivity, specificity, PPV, and NPV were 79.4%, 98.1%, 96.1%, and 89.1%, respectively (Table 2).

The optimal SI cutoff value that could differentiate between benign and malignant micronodules was 3.06, with 98% sensitivity and 91% specificity (AUC: 0.970; 95% confidence interval: 0.948–0.992; $P < 0.001$; Figure; Table 3).

4. Discussion

Thyroid nodules are commonly encountered in the general population; in recent years, the frequency of occurrence of thyroid nodules has increased (18). This increased incidence is attributed to better diagnostic accuracy and screening. Thyroid micronodules generally receive clinical attention only after being incidentally detected by the physician. The exclusion of thyroid cancer during diagnosis is the main point in the investigation of these micronodules. In recent years, thyroid cancer incidence has substantially increased, particularly that of papillary thyroid cancer (19), which can be attributed to papillary microcarcinomas sized <1 cm (20).

Shrestha et al. grouped the nodules according to the size of the maximum diameter as follows: group A, 0.5–0.9

cm; group B, 1.0–3.9 cm, and group C, ≥ 4 cm (21). The subcentimeter nodules had the highest malignancy rate. Cavallo et al. also investigated the association between nodule size and malignancy and reported that malignancy risk was inversely correlated with nodule size because smaller nodules had higher malignancy rates (22).

In our study, we evaluated 224 micronodules with FNAB, of which 108 were benign, 19 were suspected of malignancy, and 44 were malignant. The patients whose FNAB results confirmed or suspected malignancy underwent surgery. According to histopathological results, all these patients had papillary thyroid microcarcinoma. When benign, suspected malignant, and malignant nodules were evaluated based on FNAB (171 micronodules), the prevalence of malignancy in micronodules was 36.8%, which was higher than rates in other studies (21,22). Of the 224 micronodules evaluated using FNAB, 43 (19.2%) had AUS and 10 (4.5%) had ND cytology. Moon et al., who investigated 1440 nodules sized 0.2–1.0 cm in diameter using FNAB, found that 17.8% were insufficient and concluded that the nodule size was inversely proportional to insufficiency rates (23).

In 2008, Mazzaferri and Sipos recommended that FNAB should not be used for evaluating nodules of <0.5 cm in diameter because of the high rate of inadequate specimens (24). On the other hand, the American Association of Clinical Endocrinologists recommended biopsy for nodules of ≤ 1 cm diameter and with suspicious US features (10). However, the specificity, sensitivity, PPV, and NPV for these criteria considerably differ across studies. None of the US features have both high specificity and high sensitivity (6,7).

Elastography might be an additional tool for the diagnosis of thyroid carcinoma in micronodules in the general population. In the present study, we investigated the diagnostic performance of elastography for detecting malignant thyroid micronodules. We showed that ES and SI were significantly higher for malignant thyroid micronodules than for benign ones. Furthermore, the AUC of SI evaluation was greater than that of ES evaluation (0.970 vs. 0.888, respectively); therefore, we concluded that SI better reflects malignancy compared with ES in thyroid micronodules.

Table 2. Sensitivity and specificity of elastosonography scoring.

Score	Benign	Malignant	SN (%)	SP (%)	PPV (%)	NPV (%)
1–3	106	13				
4–5	2	50	79.4	98.1	96.1	89.1
Total	108	63				

SN: Sensitivity. SP: specificity. PPV: positive predictive value. NPV: negative predictive value.

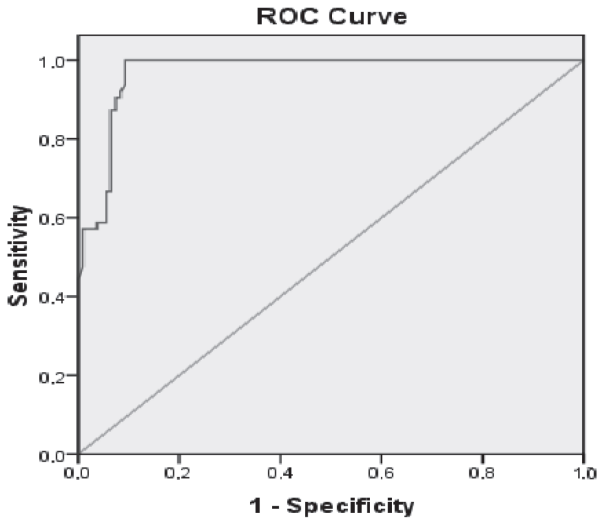


Figure. Receiver operating characteristic (ROC) curve of strain index for distinguishing malignant micronodules from benign ones (AUC = 0.970; 95% CI: 0.948–0.992).

Wang et al. reported 90.6% sensitivity and 89.4% specificity for ES of 4–5 in determining malignancy for nodules of <1 cm diameter (14). Hong et al. in their malignancy study evaluated thyroid nodules sized <1 cm and reported 90% sensitivity, 82% specificity, 79% PPV, and 91% NPV for ES of ≥ 4 (25). In our study, ES ≥ 4 represented malignancy, with sensitivity, specificity, PPV, and NPV of 79.4%, 98.1%, 96.1%, and 89.1%, respectively.

References

1. Gharib H, Papini E, Garber JR, Duick DS, Harrell RM, Hegedüs L, Paschke R, Valcavi R, Vitti P; AACE/ACE/AME Task Force on Thyroid Nodules. American Association of Clinical Endocrinologists, American College of Endocrinology, and Associazione Medici Endocrinologi medical guidelines for clinical practice for the diagnosis and management of thyroid nodules--2016 update. *Endocr Pract* 2016; 22: 622-639.
2. Hegedüs L. Clinical practice. The thyroid nodule. *N Engl J Med* 2004; 351: 1764-1771.
3. Lin JD, Chao TC, Huang BY, Chen ST, Chang HY, Hsueh C. Thyroid cancer in the thyroid nodules evaluated by ultrasonography and fine-needle aspiration cytology. *Thyroid* 2005; 15: 708-717.
4. Gharib H. Fine-needle aspiration biopsy of thyroid nodules: advantages, limitations, and effect. *Mayo Clin Proc* 1994; 69: 44-49.
5. Papini E, Guglielmi R, Bianchini A, Crescenzi A, Taccogna S, Nardi F, Panunzi C, Rinaldi R, Toscano V, Pacella CM. Risk of malignancy in nonpalpable thyroid nodules: predictive value of ultrasound and color-Doppler features. *J Clin Endocrinol Metab* 2002; 87: 1941-1946.

Table 3. Area under the curve of elastosonography scoring and strain index.

	Area under curve (%)	P-value	95% confidence interval for area under curve
ES	0.888	<0.001	0.826–0.950
SI	0.970	<0.001	0.948–0.992

The results of the present study suggested that both ES and SI evaluations are valuable methods. Although Unluturk et al. reported that elastography is not a helpful method for predicting malignancy (26), our study confirmed the usefulness of ES and SI in detecting malignant thyroid micronodules with high sensitivity and specificity. The optimal cutoff point for SI in diagnosing malignancy was 3.06 in our study. The limitation of our study was the lack of histopathological diagnosis of all nodules. Furthermore, we did not repeat FNAB in patients with AUS and ND cytology because that they did not return for follow-up.

In conclusion, the incidence of thyroid micronodules has been increasing in the general population, and the prevalence of malignancy is higher in such nodules. Previous studies have only recommended FNA of these nodules when US features are suspicious for malignancy; however, the results lack sensitivity and specificity. ES and SI are more useful measurements for diagnosing malignancy in thyroid micronodules.

11. Çakal E, Şahin M, Ünsal İÖ, Güngüneş A, Akkaymak E, Özkaya EÇ, Bozkurt NÇ, Özbek M, Delibaşı T. Elastography in the differential diagnosis of thyroid nodules. *Ultrason Imaging* 2015; 37: 251-257.
12. Şahin M, Çakal E, Özbek M, Güngüneş A, Arslan MS, Akkaymak ET, Uçan B, Ünsal İÖ, Bozkurt NÇ, Delibaşı T. Elastography in the differential diagnosis of thyroid nodules in Hashimoto thyroiditis. *Med Oncol* 2014; 31: 97.
13. Hong Y, Liu X, Li Z, Zhang X, Chen M, Luo Z. Real-time ultrasound elastography in the differential diagnosis of benign and malignant thyroid nodules. *J Ultrasound Med* 2009; 28: 861-867.
14. Wang H, Zhao L, Xin X, Wei X, Zhang S, Li Y, Gao M. Diagnostic value of elastosonography for thyroid microcarcinoma. *Ultrasonics* 2014; 54: 1945-1949.
15. Cibas ES, Ali SZ. NCI thyroid FNA state of the science conference. The Bethesda system for reporting thyroid cytopathology. *Am J Clin Pathol* 2009; 132: 658-665.
16. Rago T, Vitti P, Chiovato L, Mazzeo S, De Liperi A, Miccoli P, Viacava P, Bogazzi F, Martino E, Pinchera A. Role of conventional ultrasonography and color flow-doppler sonography in predicting malignancy in "cold" thyroid nodules. *Eur J Endocrinol* 1998; 138: 41-46.
17. Ueno E, Ito A. Diagnosis of breast cancer by elasticity imaging. *Eizo Joho Med* 2004; 36: 2-6.
18. Jiang H, Tian Y, Yan W, Kong Y, Wang H, Wang A, Dou J, Liang P, Mu Y. The prevalence of thyroid nodules and an analysis of related lifestyle factors in Beijing communities. *Int J Environ Res Public Health* 2016; 13: 442.
19. Lim H, Devesa SS, Sosa JA, Check D, Kitahara CM. Trends in thyroid cancer incidence and mortality in the United States, 1974-2013. *JAMA* 2017; 317: 1338-1348.
20. Pacini F. Thyroid microcarcinoma. *Best Pract Res Clin Endocrinol Metab* 2012; 26: 421-429.
21. Shrestha M, Crothers BA, Burch HB. The impact of thyroid nodule size on the risk of malignancy and accuracy of fine-needle aspiration: a 10-year study from a single institution. *Thyroid* 2012; 22: 1251-1256.
22. Cavallo A, Johnson DN, White MG, Siddiqui S, Antic T, Mathew M, Grogan RH, Angelos P, Kaplan EL, Cipriani NA. Thyroid nodule size at ultrasound as a predictor of malignancy and final pathologic size. *Thyroid* 2017; 27: 641-650.
23. Moon H, Son E, Kim EK, Yoon J, Kwak J. The diagnostic values of ultrasound and ultrasound-guided fine needle aspiration in subcentimeter-sized thyroid nodules. *Ann Surg Oncol* 2011; 19: 52-59.
24. Mazzaferri E, Sipsos J. Should all patients with subcentimeter thyroid nodules undergo fine-needle aspiration biopsy and preoperative neck ultrasonography to define the extent of tumor invasion? *Thyroid* 2008; 18: 597-602.
25. Hong YR, Wu YL, Luo ZY, Wu NB, Liu XM. Impact of nodular size on the predictive values of gray-scale, color-Doppler ultrasound, and sonoelastography for assessment of thyroid nodules. *J Zhejiang Univ Sci B* 2012; 13:707-16.
26. Unluturk U, Erdogan MF, Demir O, Gullu S, Baskal N. Ultrasound-elastography is not superior to gray-scale ultrasound in predicting malignancy in thyroid nodules. *Thyroid* 2012; 22: 1031-1038.