

Hepatoprotective effects of *Malva sylvestris* L. against paracetamol-induced hepatotoxicity

Liaqat HUSSAIN¹, Javaria IKRAM¹, Kanwal REHMAN², Muhammad TARIQ²,
Muhammad IBRAHIM³, Muhammad Sajid Hamid AKASH^{1,2,*}

¹College of Pharmacy, Government College University Faisalabad, Faisalabad, Pakistan

²Institute of Pharmacology, Toxicology, and Biochemical Pharmaceutics,

College of Pharmaceutical Sciences, Zhejiang University, Hangzhou, P.R. China

³Department of Applied Chemistry, Faculty of Science and Technology,
Government College University Faisalabad, Faisalabad, Pakistan

Received: 10.12.2013

Accepted: 12.02.2014

Published Online: 14.04.2014

Printed: 12.05.2014

Abstract: *Malva sylvestris* is traditionally used for the treatment of liver diseases, but sufficient pharmacological-based scientific literature is not available online to authenticate its use in liver ailments. We aimed to assess the hepatoprotective effects of *Malva sylvestris* against paracetamol-induced hepatotoxicity in mice. The extract was concentrated using a rotary evaporator and then desired concentrations of extracts were made by dissolving in normal saline. The standard drug silymarin (100 mg/kg) was used as a reference drug to compare the therapeutic effects of *Malva sylvestris*. Two different doses of *Malva sylvestris* (300 and 600 mg/kg) were administered intraperitoneally for 7 consecutive days followed by intraperitoneal administration of paracetamol (250 mg/kg). Paracetamol significantly induced oxidative stress in the liver, ultimately leading to increased serum levels of liver enzyme markers like alanine aminotransferase, aspartate aminotransferase, alkaline phosphatase, total bilirubin, and direct bilirubin. The extract of *Malva sylvestris* significantly reduced the serum levels of these elevated liver enzyme markers in a dose-dependent manner. Histopathological examination of liver tissues also showed hepatoprotective effects of *Malva sylvestris* in restoring normal functional ability of the liver. The results of our study strongly suggest that the extract of *Malva sylvestris* has strong hepatoprotective effects against paracetamol-induced liver injury, thereby scientifically affirming its traditional therapeutic role in liver injury.

Key words: Hepatotoxicity, *Malva sylvestris*, paracetamol, silymarin, liver enzyme markers

1. Introduction

The liver, being the center of metabolic functions, plays a crucial role in metabolizing a variety of xenobiotics; it is therefore more vulnerable to the toxicity of these chemicals. Hepatotoxicity, either dose-related or idiosyncratic, is considered as a global health concern and may occur as a result of drug metabolism. Because of the lack of effective treatment options, liver diseases have extremely poor prognosis and high mortality. Even though various advancements have been achieved in the field of modern medicine, liver diseases still remain a major health issue. In view of that, investigations of new therapeutic approaches are still ongoing (Choi et al., 2011; Rehman et al., 2014). One of the most typical examples of dose-related toxicity is that of paracetamol (James et al., 2003). Paracetamol is most commonly used as an analgesic and antipyretic. It is considered safe in its therapeutic doses, but overdose toxicity of paracetamol is one of the most common among the pharmaceutical product

poisonings that may cause liver injury. It is one of the leading causes of hepatic failure worldwide and it exerts hepatotoxic effects in a dose-dependent manner (Kelava et al., 2010; El-Agamy et al., 2014). Normally, paracetamol is metabolized by cytochrome P450 enzymes into an active intermediate, i.e. N-acetyl-p-benzoquinone imine (NAPQI), which is rapidly detoxified by conjugation with glutathione (McGill et al., 2012). Excessive production of NAPQI due to overdoses of paracetamol reduces the levels of free glutathione by saturating the glucuronidation and sulfation pathways, which ultimately leads to hepatic necrosis progressing to liver malfunction. Excess NAPQI binds to the mitochondrial proteins and also damages the mitochondria in hepatocytes, leading to extreme generation of free radicals followed by lipid peroxidation and finally hepatic cell death (McGill et al., 2012).

As the liver is actively involved in a variety of drug metabolism, protection of the liver from the deleterious effects of drug metabolites is of utmost importance. To

* Correspondence: sajidakash@gmail.com

treat such situations, various synthetic drugs have been developed, but most of them have numerous other side effects. From ancient times, man has always used herbs for various liver disorders as a treatment strategy, because natural remedies from traditional medicinal plants have proven to be effective alternative treatments in cases of liver injury. From various studies, it has been found that hepatoprotective effects are directly associated with phytoconstituents (Sabir and Rocha, 2008; Choi et al., 2009; Bhaskar and Balakrishnan, 2010; Huang et al., 2010; Nayak et al., 2011; Rehman et al., 2012; Ibrahim et al., 2013). All around the world, and especially in developing countries, people use traditional herbal medicines; therefore, there is a strong need to develop such a hepatoprotective medicine using natural products that can pass the safety evaluation and screening in the early phase of drug discovery because most toxic compounds are metabolized in the liver (Iwalokun et al., 2006; Adeneye, 2009; Ajiboye et al., 2010; Ahmed et al., 2013; Chanda et al., 2013). Hence, the present study is focused on the evaluation of hepatoprotective effects of *Malva sylvestris* on paracetamol-induced hepatotoxicity.

Malva sylvestris L. belongs to the family Malvaceae. It is commonly known as common mallow in Europe, gulkhaira or vilayatti kangani in Pakistan and India (Mustafa and Ali, 2011), khabazi or tole in Iran, malva in Portugal, marva in Italy, and ebeğümeci in Turkey (Tabaraki et al., 2012). Although it is found all around the world as a weed, its native regions are South Europe, North Africa, and Southwest Asia. The plant preferably grows in damp places like near oceans, marshes, ditches, river banks, and meadows (Razavi et al., 2011). It is an annual or perennial herb, reaching a height of almost 1 m. Leaves are almost heart-shaped with 5–7 lobes and flowers are bright pink with purple veins (Figure 1). *Malva sylvestris* is rich in phytoconstituents (Nehir and Karakaya, 2004; Wang, 2005; Barros et al., 2010; Çadırcı et al., 2012; Sabri et al., 2012; Tabaraki et al., 2012). It has shown potential therapeutic effects against various diseases (Jan et al., 2009; Pirbalouti et al., 2009; Marouane et al., 2011; Razavi et al., 2011). Diabetes mellitus, being an autoimmune syndrome, is among the major life-threatening diseases (Akash et al., 2012, 2013a, 2013b). Synthetic antidiabetic agents are unable to cure diabetes due to their potential side effects (Akash et al., 2012). There are varieties of plants that have the potential to cure diabetes mellitus (Romila et al., 2010; Ponnusamy et al., 2011; Akash et al., 2011, 2013c; Patel et al., 2012; Rahman et al., 2012; Arif et al., 2014). Recently, it has also been reported that the extract of *Malva sylvestris* has wound-healing potential in alloxan-induced diabetic rats (Pirbalouti et al., 2010, 2012). The extract of *Malva sylvestris* also has antiinflammatory and antiulcerogenic properties (Conforti et al., 2008; Sleiman and Daher, 2009;



Figure 1. *Malva sylvestris*.

Pirbalouti et al., 2010; Gasparetto et al., 2012; Prudente et al., 2013).

Being a potential antioxidant agent, *Malva sylvestris* may also have hepatoprotective activity; however, so far, no scientific data have been made available in the literature. The present study aimed to evaluate the hepatoprotective activity of the methanolic extract of *Malva sylvestris* L. in Swiss albino mice intoxicated with paracetamol in a dose-dependent manner.

2. Materials and methods

2.1. Drugs and chemicals

Paracetamol was purchased from Glaxo Smith Kline Ltd., Karachi, Pakistan. Silymarin was purchased from Abbott Laboratories, Karachi, Pakistan. Diagnostic kits were purchased from Merck and DiaSys Diagnostic Systems, Germany. All other chemicals and reagents used in this study were of high analytical grade and were used without further modifications.

2.2. Experimental animals

Healthy adult male Swiss albino mice (25–35 g) were used in this study. The animals were obtained from the animal house of the University of Agricultural Faisalabad, Faisalabad, Pakistan. Animals were kept in standard plastic mice cages with stainless steel coverlids in an air-conditioned room maintained at 25 ± 2 °C with a regular 12 h light/12 h dark cycle and they were provided with standard laboratory food. Free access to food and water ad libitum was provided. All the procedures involving the

animals were in accordance with the approved protocol of the Ethics Committee on Animal Experimentation of the Government College University Faisalabad, Faisalabad, Pakistan.

2.3. Plant material and preparation of extract

Fresh *Malva sylvestris* L. (whole plant) was collected from Rawalpindi District of Punjab Province, Pakistan. The plant material was identified at Arid Agricultural University, Rawalpindi, Pakistan, verified by a plant taxonomist. The voucher specimen (voucher specimen no. 2078) was deposited at Arid Agricultural University for future reference. The whole plant was washed and air-dried. The dried material was then pulverized separately into fine powder by a mechanical grinder and stored in airtight bottles. Dried powder (almost 2 kg) was soaked in 6 L of 95% methanol and was kept on a shaker for 7 consecutive days. After that, the extracts were separated by filtration and concentrated at 40 °C under reduced pressure by rotary evaporator. The extract was stored in an air-tight bottle at 4 °C for further experiments.

2.4. Experimental design

2.4.1. Animal groups

Mice were divided into 5 equal groups. Group I was the control group, treated with normal saline; group II was treated with paracetamol; group III was treated with silymarin; group IV was treated with 300 mg/kg extract of *Malva sylvestris*; and group V was treated with 600 mg/kg extract of *Malva sylvestris*. Food was withdrawn 18–24 h before the experiment, although water was given ad libitum.

Group I served as the normal control and received only normal saline (1 mL/kg daily, intraperitoneally) for 7 consecutive days, while group II received only paracetamol (250 mg/kg, intraperitoneally, suspended in normal saline) for 7 consecutive days. Group III received the standard drug silymarin at 100 mg/kg daily, intraperitoneally for 7 consecutive days, and received paracetamol (250 mg/kg daily, intraperitoneally) 3 h after the administration of silymarin. In groups IV and V, the plant extract was administered intraperitoneally in 2 different doses, i.e. MS-300 (300 mg/kg) and MS-600 (600 mg/kg), daily for 7 days, and mice received paracetamol (250 mg/kg, intraperitoneally) 3 h after the administration of the extracts.

At the end of treatment, 24 h after the last dose administration, mice were anesthetized with chloroform. Blood samples of each animal were taken by cardiac puncture using sterile disposable syringes and immediately transferred into disposable glass tubes for estimation of liver enzyme markers. Serum was obtained by centrifuging blood samples at 2500 rpm for 15 min at 4 °C and stored at –20 °C until further analysis.

2.4.2. Measurement of serum levels of liver enzyme markers and bilirubin

The collected serum was further analyzed for the estimation of liver enzyme markers. Briefly, alanine aminotransferase (ALT), alkaline phosphatase (ALP), and aspartate aminotransferase (AST) contents in the serum were estimated using commercially available kits (Merck and DiaSys Diagnostic Systems) according to the standard protocol. Total bilirubin and direct bilirubin contents in the serum were estimated via commercially available kits (Merck and DiaSys Diagnostic Systems) according to the manufacturer's instructions.

2.4.3. Histopathological examination of liver tissues

The liver tissues were dissected out and washed with ice-cold normal saline, and a small cross-section of the liver was separated out. Small pieces were fixed with 10% neutral-buffered formalin and embedded in paraffin. Tissue processing was done by dehydrating with graded ethanol (50%–100%) and clearing by xylene followed by paraffin infiltration. Liver tissue sections were cut in sizes of 4–5 µm, deparaffinized with xylene, and rehydrated with graded isopropyl alcohol and a drop of water. Water was removed and slides were oven-dried. After tissue fixation, staining was done with hematoxylin and eosin. The stained sections of slides were examined under high-resolution microscope and photographs were taken.

2.5. Statistical analysis

The results are presented as mean ± SD. Statistical analysis was performed using one-way analysis of variance followed by the Tukey–Kramer multiple comparison test using Graph Pad Prism 5 (Graph Pad Software Inc., USA). $P < 0.05$ was considered statistically significant.

3. Results

3.1. Effect of *Malva sylvestris* on liver enzyme markers

Biochemical analysis of liver enzyme markers signified that the use of paracetamol in high doses strikingly raised the serum levels of liver enzyme markers ALT, AST, and ALP as compared to the control group treated with normal saline (Figure 2). Treatment with methanolic extract of *Malva sylvestris* and standard drug silymarin showed hepatoprotective activity against paracetamol-induced hepatotoxicity by maintaining the serum levels of ALT, AST, and ALP at markedly reduced levels in a dose-dependent manner (Figure 2).

We also measured the serum levels of total bilirubin and direct bilirubin in all treated groups. The group treated with paracetamol alone exhibited high levels of bilirubins as compared to the control group (Figure 3). Treatment with methanolic extract of *Malva sylvestris* at 2 different doses decreased the serum levels of bilirubins more significantly when directly compared with paracetamol-

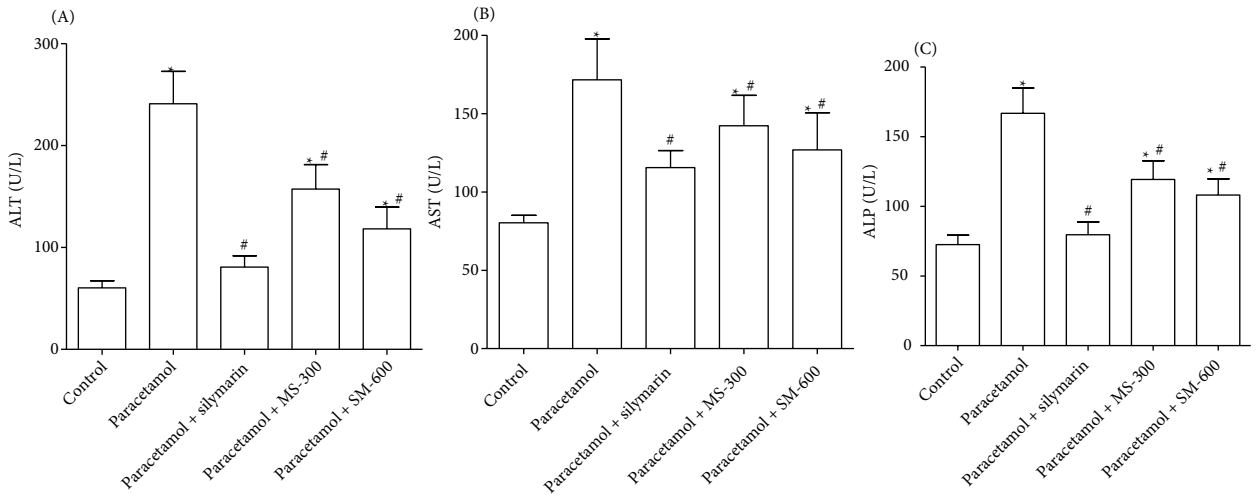


Figure 2. Estimation of ALT (A), AST (B), and ALP (C) in the serum of rats treated with normal saline, paracetamol, silymarin, MS-300 (*M. sylvestris*, 300 mg/kg), and MS-600 (*M. sylvestris*, 600 mg/kg). Values are expressed as mean ± SD for 5 rats in each group. *: P < 0.05, the value of experimental groups is significantly different from the control; #: P < 0.05, the value of experimental groups is significantly different from the group treated with paracetamol. ALT: Alanine aminotransferase, AST: aspartate aminotransferase, ALP: alkaline phosphatase.

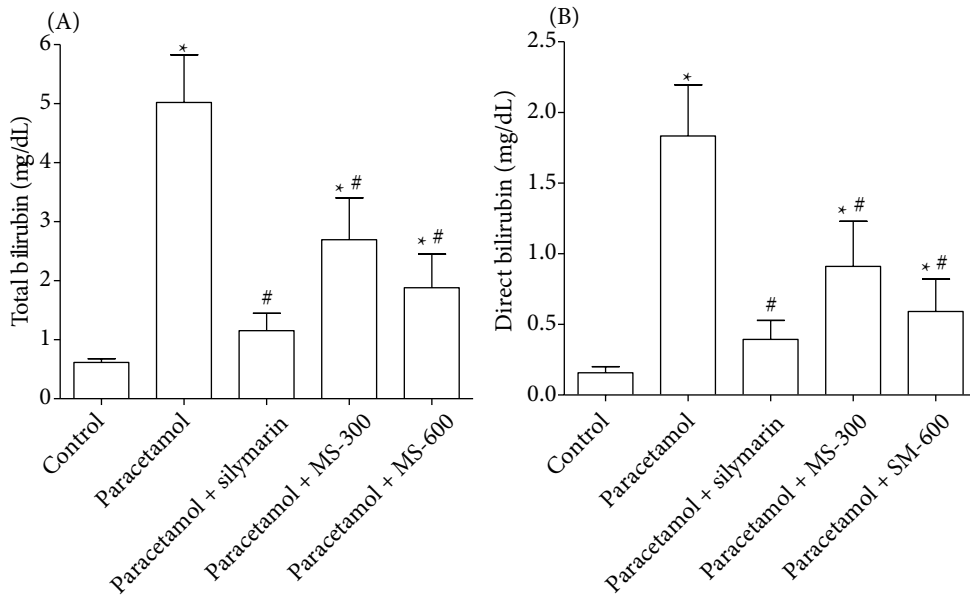


Figure 3. Estimation of total bilirubin (A) and direct bilirubin (B) in the serum of rats treated with normal saline, paracetamol, silymarin, MS-300 (*M. sylvestris*, 300 mg/kg), and MS-600 (*M. sylvestris*, 600 mg/kg). Values are expressed as mean ± SD for 5 rats in each group. *: P < 0.05, the value of experimental groups is significantly different from the control; #: P < 0.05, the value of experimental groups is significantly different from the group treated with paracetamol.

treated mice. We also found a nonsignificant difference between the silymarin-treated group and the group treated with a high dose (600 mg/kg) of *Malva sylvestris* (Figure 3).

3.2. Histopathological examination of the liver

Histopathological analysis revealed that group I, treated with normal saline, showed normal sections of

liver tissues (Figure 4A), whereas the liver sections of paracetamol-treated mice lost their normal architecture. Severe congestion of blood vessels along with hepatic cell necrosis, vacuolization, eosinophils, macrophages, plasma cells infiltration, degeneration of hepatocytes nuclei, and fibrosis were seen (Figure 4B). Silymarin treatment

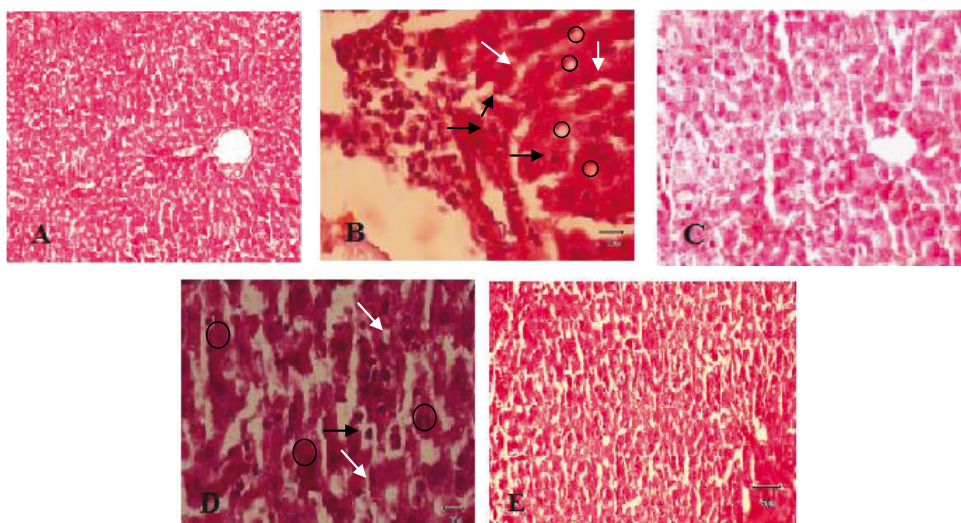


Figure 4. Histopathological changes in the liver of control and treated animals. **A-** Control group with no treatment. **B-** Paracetamol-treated group showing macrophages, plasma cell infiltration (black arrows), vacuolization (white arrows), and cell necrosis (circles). **C-** Group treated with silymarin followed by paracetamol showing binucleated cells with slight vacuolization and infiltration. **D-** Group treated with MS-300 followed by paracetamol. **E-** Group treated with MS-600 followed by paracetamol. Figures A and E are 200× and B, C, and D are 100× magnification.

followed by paracetamol administration displayed normal structure of hepatocytes, mild infiltration, and vacuolization (Figure 4C). Treatment with *Malva sylvestris* extract (MS-300) followed by paracetamol administration showed few binucleated cells while most cells were normal, with slight congestion, vacuolization, and infiltration (Figure 4D). However, in the case of MS-600, the recovery stage had well-arranged hepatocytes and no necrosis was evident (Figure 4E).

4. Discussion

Medicinal plant-based medicines are potential sources of naturally occurring phytoconstituents that may act in a variety of ways to suppress the generation of reactive oxygen species. These phytoconstituents have broad ranges of pharmacological activities (Karaman et al., 2010; Orhan et al., 2012; Zayova et al., 2013; Zia-Ul-Haq et al., 2013). Glutathione is one of the major antioxidants that protect the liver from toxic effects of paracetamol (Prescott, 2005), but overdoses of paracetamol may result in the depletion of glutathione stores, which ultimately leads to the release of serum levels of liver enzyme biomarkers indicating mitochondrial damage (McGill et al., 2012; da Rosa et al., 2012). Paracetamol-induced hepatotoxicity results in the elevated levels of liver enzyme markers such as ALT, AST, and ALP. Elevated levels of these enzymes in the serum represent the loss of functional integrity due to the cellular leakage of these enzymes from the cell membrane of the liver, which is reflected by the histopathological alterations

(Ramaiah 2007; Sreelatha et al., 2009; Aseervatham et al., 2014). Estimations of these liver enzyme markers in the serum reflect the normal and/or abnormal condition of the liver. Methanolic extract of *Malva sylvestris* maintained the serum levels of ALT, AST, and ALP. In the present study, we used 2 doses of *Malva sylvestris* (300 mg/kg and 600 mg/kg). We found that *Malva sylvestris* showed hepatoprotective effects in a dose-dependent manner. A high dose of *Malva sylvestris* showed a nonsignificant difference with the hepatoprotective effects of standard drug silymarin (Figure 2).

Similarly, the elevated levels of bilirubin in serum are also attributed to the paracetamol-induced hepatotoxicity, which is usually due to the abnormal production of bilirubin in the liver (Aseervatham et al., 2014). Bilirubin level is also considered as one of the most important liver function tests as it reflects the functional integrity of the liver. In the present study, we measured the serum levels of total bilirubin and direct bilirubin. The significant reduction in the serum levels of these bilirubins in *Malva sylvestris*-treated mice was observed in a dose-dependent manner (Figure 3). The observed hepatoprotective effect of *Malva sylvestris* in paracetamol-induced hepatotoxicity might be due to the presence of an active concentration of phytoconstituents that might restore the glutathione levels in hepatocytes, due to which the functional integrity of the liver was increased, as was evident from the decreased levels of liver enzyme markers and improved live histopathological examinations of liver.

In conclusion, the results of the present study reveal that the methanolic extract of *Malva sylvestris* can significantly protect the liver from the damaging effects of paracetamol in a dose-dependent manner by considerably decreasing the serum levels of liver enzyme markers. The decreased serum levels of these enzymes were further accompanied by the improvement of liver histology in *Malva sylvestris*-treated mice, which remarkably exhibited the hepatoprotective effects

of *Malva sylvestris* in paracetamol-induced hepatotoxicity. The hepatoprotective effects of *Malva sylvestris* scientifically validate the traditional use of *Malva sylvestris* in liver ailments.

Acknowledgment

Authors would like to acknowledge Government College University Faisalabad for financial support to conduct this study.

References

- Adeneye AA (2009). Protective activity of the stem bark aqueous extract of *Musanga cecropioides* in carbon tetrachloride- and acetaminophen-induced acute hepatotoxicity in rats. *Afr J Tradit Complement Altern Med* 6: 131–138.
- Ahmed H, Zahab HAE, Alswiai G (2013). Purification of antioxidant protein isolated from *Peganum harmala* and its protective effect against CCl₄ toxicity in rats. *Turk J Biol* 37: 39–48.
- Ajiboye TO, Salau AK, Yakubu MT, Oladiji AT, Akanji MA, Okogun JI (2010). Acetaminophen perturbed redox homeostasis in Wistar rat liver: protective role of aqueous *Pterocarpus osun* leaf extract. *Drug Chem Toxicol* 33: 77–87.
- Akash MSH, Rehman K, Chen S (2013a). An overview of valuable scientific models for diabetes mellitus. *Curr Diabetes Rev* 9: 286–293.
- Akash MSH, Rehman K, Chen S (2013b). Role of inflammatory mechanisms in pathogenesis of type 2 diabetes mellitus. *J Cell Biochem* 114: 525–531.
- Akash MSH, Rehman K, Chen S (2013c). Effects of coffee on type 2 diabetes mellitus. *Nutrition* DOI:10.1016/j.nut.2013.11.020 (in press).
- Akash MSH, Rehman K, Rasool F, Sethi A, Abrar MA, Irshad A, Abid A, Murtaza G (2011). Alternate therapy of type 2 diabetes mellitus (T2DM) with *Nigella* (Ranunculaceae). *J Med Plants Res* 5: 6885–6889.
- Akash MSH, Shen Q, Rehman K, Chen S (2012). Interleukin-1 receptor antagonist: a new therapy for type 2 diabetes mellitus. *J Pharm Sci* 101: 1647–1658.
- Arif T, Sharma B, Gahlaut A, Kumar V, Dabur R (2014). Anti-diabetic agents from medicinal plants: A review. *Chem Bio Lett* 1: 1–13.
- Aseervatham GS, Sivasudha T, Sasikumar JM, Christabel PH, Jeyadevi R, Ananth DA (2014). Antioxidant and hepatoprotective potential of *Pouteria campechiana* on acetaminophen-induced hepatic toxicity in rats. *J Physiol Biochem* 70: 1–14.
- Barros L, Carvalho AM, Ferreira ICFR (2010). Leaves, flowers, immature fruits and leafy flowered stems of *Malva sylvestris*: a comparative study of the nutraceutical potential and composition. *Food Chem Toxicol* 48: 1466–1472.
- Bhaskar VH, Balakrishnan N (2010). Protective effects of *Pergularia daemia* roots against paracetamol and carbon tetrachloride-induced hepatotoxicity in rats. *Pharm Biol* 48: 1265–1272.
- Çadırcı E, Süleyman H, Gürbüz P, Kuruüzüm Uz A, Güvenalp Z, Demirezer LÖ (2012). Anti-inflammatory effects of different extracts from three *Salvia* species. *Turk J Biol* 36: 59–64.
- Chanda S, Rakholiya K, Dholakia K, Baravalia Y (2013). Antimicrobial, antioxidant, and synergistic properties of two nutraceutical plants: *Terminalia catappa* L. and *Colocasia esculenta* L. *Turk J Biol* 37: 81–91.
- Choi JH, Choi CY, Lee KJ, Hwang YP, Chung YC, Jeong HG (2009). Hepatoprotective effects of an anthocyanin fraction from purple-fleshed sweet potato against acetaminophen-induced liver damage in mice. *J Med Food* 12: 320–326.
- Choi JH, Kim DW, Yun N, Choi JS, Islam MN, Kim YS, Lee SM (2011). Protective effects of hyperoside against carbon tetrachloride-induced liver damage in mice. *J Nat Prod* 74: 1055–1060.
- Conforti F, Sosa S, Marrelli M, Menichini F (2008). In vivo anti-inflammatory and in vitro antioxidant activities of Mediterranean dietary plants. *J Ethnopharmacol* 116: 144–151.
- da Rosa EJ, da Silva MH, Carvalho NR, Bridi JC, da Rocha JB, Carbajo-Pescador S, Mauriz JL, González-Gallego J, Soares FA (2012). Reduction of acute hepatic damage induced by acetaminophen after treatment with diphenyl diselenide in mice. *Toxicol Pathol* 40: 605–613.
- El-Agamy DS, Makled MN, Gamil NM (2014). Protective effects of BML-111 against acetaminophen-induced acute liver injury in mice. *J Physiol Biochem* 70: 141–149.
- Gasparetto JC, Martins CAF, Hayashi SS, Otuky ME, Pontarolo R (2012). Ethnobotanical and scientific aspects of *Malva sylvestris* L.: a millennial herbal medicine. *J Pharm Pharmacol* 64: 172–189.
- Huang B, Ban X, He J, Tong J, Tian J, Wang Y (2010). Hepatoprotective and antioxidant activity of ethanolic extracts of edible lotus (*Nelumbo nucifera* Gaertn.) leaves. *Food Chem* 120: 873–878.
- Ibrahim M, Farooq T, Hussain N, Hussain A, Gulzar T, Hussain I, Akash MSH, Rehmani FS (2013). Acetyl and butyryl cholinesterase inhibitory sesquiterpene lactones from *Amberboa ramosa*. *Chem Cent J* 7: 116.
- Iwalokun BA, Efedede BU, Alabi-Sofunde JA, Oduala T, Magbagbeola OA, Akinwande AI (2006). Hepatoprotective and antioxidant activities of *Vernonia amygdalina* on acetaminophen-induced hepatic damage in mice. *J Med Food* 9: 524–530.
- James LP, Mayeux PR, Hinson JA (2003). Acetaminophen-induced hepatotoxicity. *Drug Metab Dispos* 12: 1499–1506.
- Jan G, Khan MA, Gul F (2009). Ethnomedicinal plants used against jaundice in Dir Kohistan Valleys (NWFP), Pakistan. *Ethno Leaflets* 13: 1029–1041.

- Karaman S, Tutem E, Baskan KS, Apak R (2010). Comparison of total antioxidant capacity and phenolic composition of some apple juices with combined HPLC-CUPRAC assay. *Food Chem* 120: 1201–1209.
- Kelava T, Cavar I, Culo F (2010). Influence of small doses of various drug vehicles on acetaminophen-induced liver injury. *Can J Physiol Pharmacol* 88: 960–967.
- Marouane W, Soussi A, Murat J, Bezzine S, Feki AE (2011). The protective effect of *Malva sylvestris* on rat kidney damaged by vanadium. *Lipids Health Dis* 10: 65–72.
- McGill MR, Sharpe MR, Williams CD, Taha M, Curry SC, Jaeschke H (2012). The mechanism underlying acetaminophen-induced hepatotoxicity in humans and mice involves mitochondrial damage and nuclear DNA fragmentation. *J Clin Invest* 122: 1574–1583.
- Mustafa A, Ali M (2011). New steroidal lactones and homomonoterpenic glucoside from fruits of *Malva sylvestris* L. *Acta Pol Pharm* 68: 393–401.
- Nayak SS, Jain R, Sahoo AK (2011). Hepatoprotective activity of *Glycosmis pentaphylla* against paracetamol-induced hepatotoxicity in Swiss albino mice. *Pharm Biol* 49: 111–117.
- Nehir ES, Karakaya S (2004). Radical scavenging and iron-chelating activities of some greens used as traditional dishes in Mediterranean diet. *Int J Food Sci Nutr* 55: 67–74.
- Orhan DD, Özçelik B, Hoşbaş S, Vural M (2012). Assessment of antioxidant, antibacterial, antimycobacterial, and antifungal activities of some plants used as folk remedies in Turkey against dermatophytes and yeast-like fungi. *Turk J Biol* 36: 672–686.
- Patel D, Prasad S, Kumar R, Hemalatha S (2012). An overview on antidiabetic medicinal plants having insulin mimetic property. *Asian Pac J Trop Biomed* 2: 320–330.
- Pirbalouti AG, Azizi S, Koohpayeh A (2012). Healing potential of Iranian traditional medicinal plants on burn wounds in alloxan-induced diabetic rats. *Braz J Pharm* 21: 382–391.
- Pirbalouti AG, Azizi S, Koohpayeh A, Hamed B (2010). Wound healing activity of *Malva sylvestris* and *Punica granatum* in alloxan-induced diabetic rats. *Acta Pol Pharm* 67: 511–516.
- Pirbalouti AG, Yousefi M, Nazari H, Karimi I, Koohpayeh A (2009). Evaluation of burn healing properties of *Arnebia euchroma* and *Malva sylvestris*. *Electr J Biol* 5: 62–66.
- Ponnusamy S, Ravindran R, Zinjarde S, Bhargava S, Ravi Kumar A (2011). Evaluation of traditional Indian antidiabetic medicinal plants for human pancreatic amylase inhibitory effect in vitro. *Evid Based Complement Alternat Med* 2011: 515647.
- Prescott L (2005). Oral or intravenous N-acetylcysteine for acetaminophen poisoning? *Ann Emerg Med* 5: 409–413.
- Prudente AS, Loddi AM, Duarte MR, Santos AR, Pochapski MT, Pizzolatti MG, Hayashi SS, Campos FR, Pontarolo R, Santos EA et al. (2013). Pre-clinical anti-inflammatory aspects of a cuisine and medicinal millennial herb: *Malva sylvestris* L. *Food Chem Toxicol* 58: 324–331.
- Rahman MM, Hossain MA, Siddique SA, Biplab KP, Uddin MH (2012). Antihyperglycemic, antioxidant and cytotoxic activities of *Alocasia macrorrhizos* (Linn.) rhizomes extract. *Turk J Biol* 36: 574–579.
- Ramaiah SK (2007). A toxicologist guide to the diagnostic interpretation of hepatic biochemical parameters. *Food Chem Toxicol* 45: 1551–1557.
- Razavi SM, Zarrini G, Molavi G, Ghasemi G (2011). Bioactivity of *Malva sylvestris* L., a medicinal plant from Iran. *Iranian J Basic Med Sci* 14: 574–579.
- Rehman K, Akash MSH, Azhar S, Khan SA, Abid R, Waseem A, Murtaza G, Sherazi TA (2012). A biochemical and histopathologic study showing protection and treatment of gentamicin-induced nephrotoxicity in rabbits using vitamin C. *Afr J Tradit Complement Altern Med* 9: 360–365.
- Rehman K, Iqbal MJ, Zahra N, Akash MSH (2014). Liver stem cells: from preface to advancements. *Curr Stem Cell Res Ther* 9: 10–21.
- Romila Y, Mazumder PB, Choudhary MD (2010). A review on antidiabetic plants used by the people of Manipur characterized by hypoglycemic activity. *J Sci Technol* 6: 167–175.
- Sabir SM, Rocha JB (2008). Water-extractable phytochemicals from *Phyllanthus niruri* exhibit distinct in vitro antioxidant and in vivo hepatoprotective activity against paracetamol-induced liver damage in mice. *Food Chem* 111: 845–851.
- Sabir FZ, Belarbi M, Sabri S, Alsayadi MMS (2012). Phytochemical screening and identification of some compounds from mallow. *J Nat Prod Plant Resour* 2: 512–516.
- Sleiman NH, Daher CF (2009). *Malva sylvestris* water extract: a potential anti-inflammatory and anti-ulcerogenic remedy. *Planta Med* 75: 1010.
- Sreelatha S Padma PR Umadevi M (2009). Protective effects of *Coriandrum sativum* extracts on carbon tetrachloride-induced hepatotoxicity in rats. *Food Chem Toxicol* 47: 702–708.
- Tabaraki R, Yosefi Z, Gharneh HAA (2012). Chemical composition and antioxidant properties of *Malva sylvestris* L. *J Res Agri Sci* 8: 59–68.
- Wang ZY (2005). Impact of anthocyanin from *Malva sylvestris* on plasma lipids and free radical. *J For Res* 16: 228–232.
- Zayova E, Stancheva I, Geneva M, Petrova M, Dimitrova L (2013). Antioxidant activity of in vitro propagated *Stevia rebaudiana* Bertoni plants of different origins. *Turk J Biol* 37: 106–113.
- Zia-Ul-Haq M, Ahmad S, Qayum M, Ercişli S (2013). Compositional studies and antioxidant potential of *Albizia lebbek* (L.) Benth. pods and seeds. *Turk J Biol* 37: 25–32.