

## Age-Dependent Cranial Variations in *Mesocricetus brandti* (Mammalia: Rodentia) Distributed in Turkey

Nuri YİĞİT

Department of Biology, Faculty of Science, Ankara University, 06100 Beşevler, Ankara - TURKEY

Received: 08.03.2002

**Abstract:** Animals were assigned to four age groups according to molar wear, field notes and external and cranial measurements. Six days-old animals were referred to newborn, up to 30 days as young and thereafter as adult; animals with very worn molars were considered old. In addition to the statistical differences among age groups, it was determined that the main morphological differences were in the interorbital constriction, the shape of the braincase, the ridges and the position of occipital condyles. While the incisors and the first molars erupted in seven days-old animals, the second and third molars begun to erupt after seven and 30 days, respectively. Thus, it was concluded that the characteristics of animals younger than 30 days-old, and the cranial variations in the skull morphologies of adult and old animals should not be taken into consideration in taxonomic evaluations.

**Key Words:** *Mesocricetus brandti*, age variation, cranial variation, Turkey

### Türkiye'de Yayılış Gösteren *Mesocricetus brandti* (Mammalia: Rodentia)'de Yaşa Bağlı Kafatası Varyasyonları

**Özet:** Molar dişlerin çigneme yüzeylerindeki aşınma durumu, arazi notları, eksternal ve kafatası ölçüleri dikkate alınarak, örnekler; bir haftalık yavru, 30 günlükler genç, 30 günün üzerindeki ergin ve dişi aşınımlı olanlar yaşlı olmak üzere 4 yaş grubuna ayrıldı. Yaş grupları arasında istatistik farklılıkların yanında, interorbital bölgede, beyin kapsülün eğiminde, kafadaki kabarık hatlarda, oksipital kondillerin durumunda morfolojik farklılıklar saptandı. Ayrıca yavrularda incisor dişler ve birinci molar çıkmışken, ikinci molarların 7 günden sonra, üçüncü molarların ise 30 günden sonra alveolar boşluktan tam olarak çıktığı saptandı. Buna göre, 30 günden daha genç örneklerin ölçüleri ve morfolojik özellikleri ile ergin ve yaşlıların kafa morfolojilerindeki yaşa bağlı farklılıkların taksonomik değerlendirilmelerinde dikkate alınmaması gerektiği belirlendi.

**Anahtar Sözcükler:** *Mesocricetus brandti*, kafatası varyasyonlar, Türkiye

### Introduction

Hamsters range across the Palaearctic region (1-5). Species of the genus *Mesocricetus* were reported from various localities in Anatolia by Nehring (6), Neuhäuser (7), Osborn (8), Hamar and Schutowa (9), Steiner and Vauk (10), Lehmann (11), Sickenberg (12), Felten et al. (13), Spitzenberger (14), Lyman and O'Brien (15), Doğramacı et al. (16), and Yiğit et al. (17,18). *Mesocricetus auratus* (Waterhouse, 1938), *Mesocricetus raddei* Nehring, 1894, *Mesocricetus newtoni* Nehring, 1898, and *Mesocricetus brandti* Nehring, 1898, have been considered valid taxa by several authors (4,5). However, the taxonomic status of species is still under discussion (1-4,18). Of these species, *M. brandti* was first described from Georgia by Nehring (6). Subsequently, this species was recorded from many localities in Asiatic Turkey (11-18). Apart from these distributional and taxonomical records, the reproductive biology and

postnatal development of *M. brandti* were first investigated by Yiğit et al. (17). In addition to these studies, Yiğit et al. (18) and Harrison (19) reported age-dependent cranial variations in the genus *Mesocricetus*. These papers show that there are remarkable age-dependent cranial variations in *M. brandti*. All these should be taken into consideration to avoid incorrect taxonomic evaluations. Therefore, the aim of this study was to determine age-dependent cranial variations in *M. brandti*, and to evaluate their taxonomic implication.

### Materials and Methods

Specimens were collected from different localities in central Anatolia, and were examined with respect to the morphological characteristics of the skull. External and cranial measurements (mm) along with weight (g) were taken for each age group of specimens (claw length was

included in hind foot measurements), and all specimens were skinned in the standard museum manner. Specimens showing lactation, pregnancy, embryos or swollen testes were recorded in the field, and were referred to as adults. The breeding colonies (seven pairs) from live captured animals were established separately in the cages. Animals were provided with nesting materials, food (wheat seeds, fresh grass and carrot) and water. After birth occurred, pups were killed at intervals of 3, 7, 14, 21, 28, 35, 42, 49, 56 and 60 days in order to examine the cranial variations. Specimens were assigned to different age groups according to the field records, the wear of the teeth, and the external criteria given by Yiğit et al. (17). Age-dependent cranial and teeth variations were drawn under a binocular microscope. Biometric evaluations were performed by Student's t-tests (Microsoft Excel, two samples assuming unequal variance). The skins and skulls are deposited at the University of Ankara, Faculty of Science.

Abbreviations used in the text: ZB: Zygomatic breadth, IC: Interorbital constriction, CBL: Condylobasal length, ONL: Occipitonasal length, BL: Basal length, NL: Nasal length, MAB: Mastoid breadth, OW: Occipital width, DL: Diastema length, PL: Palatal length, IFL: Incisiva foramina length, MAL: Mandible length, ML: Upper molar alveolar length, M1L: Length of first upper molar, M2L: Length of second upper molar, M3L: Length of third upper molar, mL: Lower molar alveolar length, m1L: Length of first lower molar, m2L: Length of second lower molar, m3L: Length of third lower molar.

### Results and Discussion

The general aspects of adult and old skulls were as follows: the skull morphology of *M. brandti* exhibits the peculiarities of the genus *Mesocricetus*; the rostrum of adults short and broad, the nasal bones reach the middle of the anterior root of the zygomatic arch. The anterior tip of nasal bones projects beyond the incisors. The squamosal and maxillary processes of the zygomatic arch are relatively slender and slightly widened laterally. The supraorbital ridges are weakly developed in adults but are very pronounced in old individuals. These ridges strikingly border the parietal and interparietal bones. The brain case is narrowed and smooth. The lateral edge of the auditory meatus is invisible from the dorsal view, and its anterior rim does not come into contact with the squamosal of the zygomatic arch. The occipital condyles

are the most posteriorly projecting point in the planar view of the adult and old individuals, but are not visible in young skulls, being covered by the supraoccipital region (Figs. 1-3).

The teeth and age groups were as follows: the incisors are opisthodont, broad and smooth anteriorly. The molars have biserial cusps. These findings are consistent with those of Harrison and Bates (1991). The molar teeth are weakly brachyodont in adults, but are markedly so in old animals. The first molars, both upper and lower, bear three cusps with two lingual and labial folds. The remaining molars have two cusps each with one lingual and one labial fold. The first and the second upper molars have four roots, and the third one has three. All the lower molars have two roots. The external measurements during the postnatal developments are presented in Table 1 (17). These measurements along with the wear of

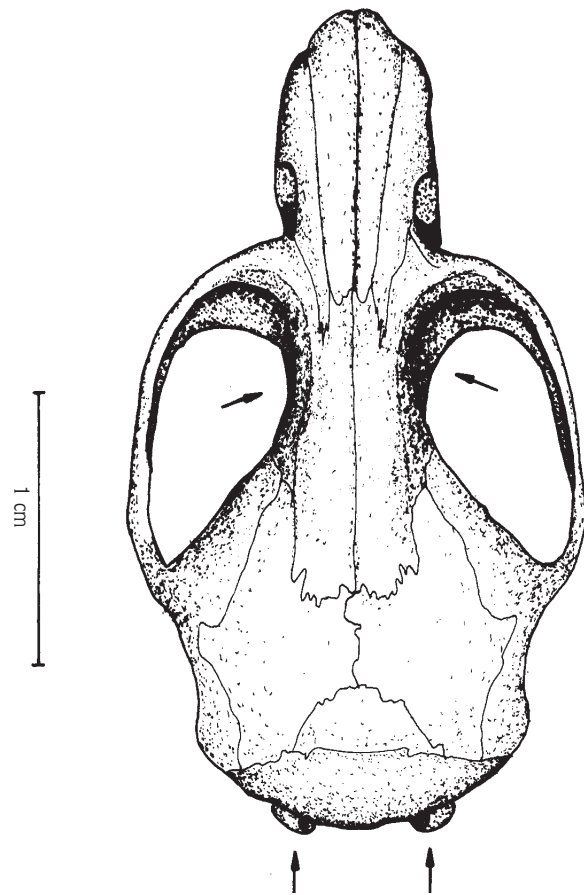


Fig. 1. Skull in dorsal view of an adult *Mesocricetus brandti*. Arrows indicate the interorbital region and the posterior tip of the occipital condyles.

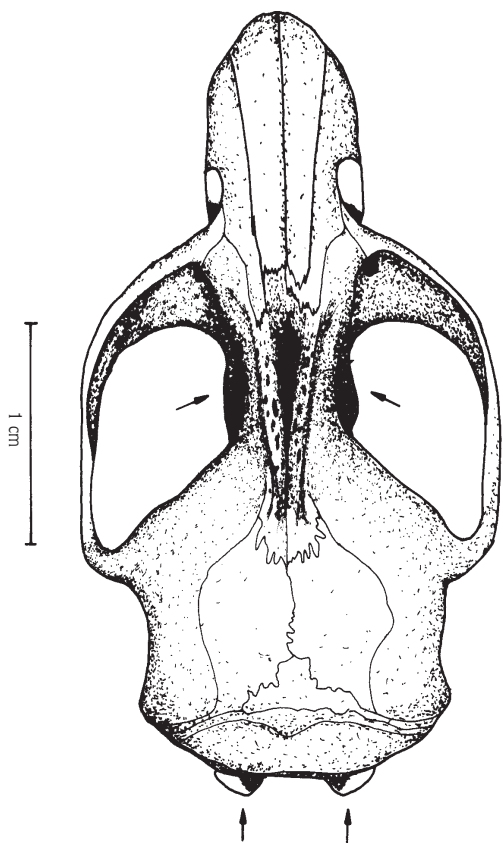


Fig. 2. Dorsal view of skull (old), the arrows show IC region and posterior tip of occipital condyles.

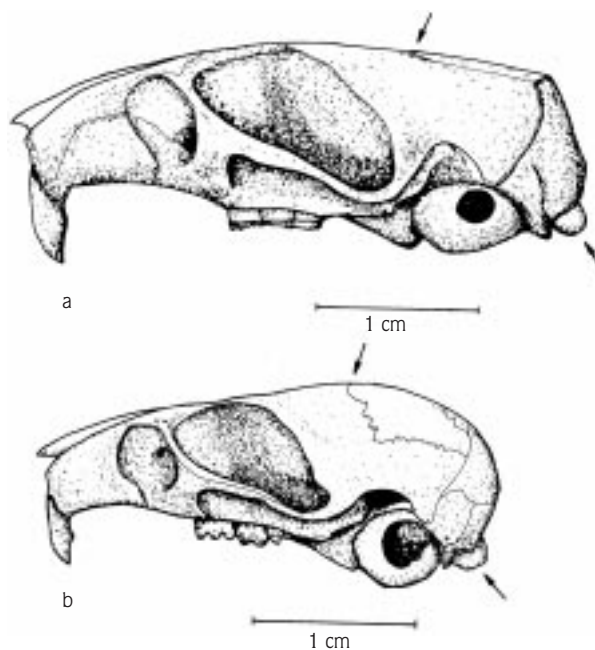


Fig. 3. a: Lateral view of old skull, the arrows show the smooth braincase and posterior tip of occipital condyles.  
b: Lateral view of young skull, the arrows show curved brain case and posterior tip of occipital condyles.

Characters (mm)	Total length	Tail length	Hind foot length	Ear length
Birth N = 38	40.5 (36-45)	4.0 (3-6)	3.9 (3-5)	- -
7 days old N = 35	57.6 (51-73)	6.0 (5-9)	7.6 (6-10)	4.0 (3-6)
14 days old N = 32	74.6 (64-91)	12.1 (9-17)	11.5 (10-14)	7.3 (6-9)
21 days old N = 30	92.4 (71-118)	15.0 (12-19)	15.2 (13-18)	13.3 (9-17)
30 days old N = 27	110.1 (96-129)	17.2 (15-21)	16.5 (14-18)	17.6 (14-19)
38 days old N = 27	119.7 (106-140)	18.0 (15-21)	17.7 (16-20)	18.5 (16-21)
45 days old N = 27	126.1 (110-145)	18.0 (15-22)	18.1 (16-20)	19.1 (16-21)

Table 1. Descriptive statistics (mean and range) of external measurements in the different ages of *M. brandti*. N = Specimen numbers. After Yiğit et al. (17).

molar surfaces and cranial characteristics were also considered to separate animals into age groups. Thus, animals were assigned to four different age groups: newborn, young, adult and old. It was determined that the incisors erupted at the age of three days and  $M_1 - M^1$  just appeared at the end of the first week after birth. In seven-day-old animals, the enamel fields on molars were closed, and the molars had protruded cusps just as in the bunodont teeth. These animals were classified as newborn. The second molars erupted after a week, but the third molars were still in the alveolar cavity. The third molars completed eruption by the age of 30 days, but still did not reach the level of the second molars. The enamel fields, especially on the third molars, were almost closed, or not completely opened at this age. These animals between six and 30 days old were referred to as young. Animals older than 30 days showed third molars completely erupted from the alveolar cavity and almost reaching the level of the second molars. They were considered adults (Figs. 4. a, b). The cusps of these animals were relatively less marked and narrow. Other specimens with worn molars were considered old, and their cusps were connected to each other and almost disappeared (Fig. 4.c). In the upper molar tooth row, the measurements of  $M1L$  ranged from 2.1 to 2.6,  $M2L$  1.6 to 2.1, and  $M3L$  1.3 to 2.0. The measurements of the lower molar tooth row were similar to those of the upper molars. When the means of molar teeth were considered, it was seen that the means of teeth measurements were

very close to each other (Table 2). When the data set of molar teeth measurements were compared between the age groups young – adult, young – old, and adult – old, it was seen that  $M3L$  and  $mL$  showed differences between the young – adult and young – old groups. In addition,  $m3L$  was also found to be statistically significant in young – old and adult – old animals ( $P < 0.05$ ), and there were no statistical differences in the data set of other teeth measurements among the age groups (Table 3).

The developments on cranial morphology and measurements: Skulls were first obtained from young animals between three and seven days old, but their measurements were not taken because of insufficient ossification, which resulted in broken skulls. The skulls of young animals up to 30 days old showed very marked differences from those of adults and old ones. As age progressed, the differences mostly originated from the shape of the braincase, the enamel pattern of molars and the width of IC (Figs. 1-4). Besides teeth measurements and morphological differences, the measurements of some cranial characteristics were also found to differ between the age groups. The ranges of cranial measurements of young animals were found to be usually below those of adult and old animals except for the measurements of IC and molars. On the other hand, the cranial measurements of adults were within the range of those of old animals (Table 2). Although the means of ZB, IC, CBL, ONL, BL, NL, MAB, OW, DL, PL, IFL and MAL were similar, the data set of these characteristics was

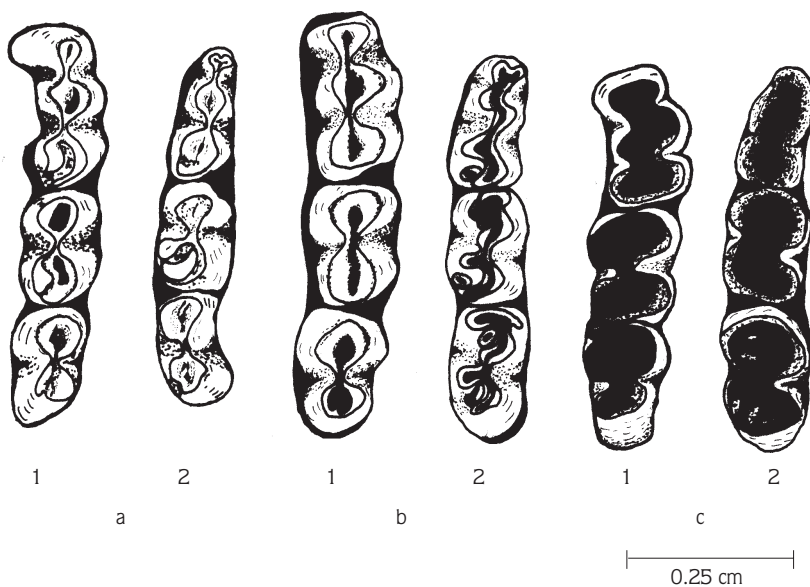


Fig. 4. The molar teeth rows (right side) in three age groups. a: young, b: adult, c: old. 1: maxillar, 2: mandibular.

Cranial Measurements (mm)	Age groups		
	Young (N = 14) (7-30 days old)	Adult (N = 14) 30 days < adults	Old (N = 14) (teeth worn)
ZB	14.0 ± 1.35 (11.7–16.0)	17.8 ± 1.61 (16.2–22.5)	19.6 ± 1.27 (16.8–21.7)
IC	4.2 ± 0.35 (3.3–4.6)	3.6 ± 0.49 (2.6–4.4)	3.4 ± 0.56 (2.8–4.9)
CBL	24.4 ± 2.67 (18.9–28.5)	31.9 ± 2.80 (29.1–38.8)	34.3 ± 2.06 (30.4–37.5)
ONL	25.4 ± 2.54 (20.5–28.9)	32.6 ± 2.83 (29.3–39.3)	35.4 ± 1.65 (31.7–38.4)
BL	22.8 ± 2.83 (17.5–26.4)	30.1 ± 2.71 (27.3–36.6)	32.7 ± 1.68 (29.0–35.6)
NL	9.7 ± 1.19 (7.3–11.1)	12.9 ± 1.42 (10.5–15.6)	14.4 ± 1.04 (13.0–15.9)
MAB	7.9 ± 0.99 (10.7–13.0)	9.6 ± 0.87 (8.2–10.8)	9.9 ± 0.82 (8.4–11.0)
OW	11.9 ± 0.69 (10.7–13.0)	13.5 ± 0.69 (12.4–15.1)	14.1 ± 0.70 (13.0–15.5)
DL	6.9 ± 0.95 (4.9–7.9)	9.4 ± 1.16 (7.9–12.5)	10.3 ± 0.66 (8.9–11.4)
PL	12.4 ± 1.41 (9.8–14.4)	16.2 ± 1.64 (14.2–20.4)	17.4 ± 0.64 (16.3–18.6)
IFL	3.9 ± 0.72 (2.5–5.0)	5.0 ± 0.45 (4.0–5.7)	5.9 ± 0.37 (5.2–6.5)
MAL	15.7 ± 2.18 (10.6–18.1)	20.4 ± 1.58 (18.1–24.2)	22.0 ± 1.03 (19.7–23.6)
ML	5.6 ± 0.44 (4.9–6.3)	6.2 ± 0.27 (5.6–6.8)	6.3 ± 0.24 (5.8–6.5)
M1L	2.3 ± 0.12 (2.1–2.5)	2.3 ± 0.13 (2.1–2.5)	2.3 ± 0.16 (2.1–2.6)
M2L	1.7 ± 0.10 (1.6–1.8)	1.8 ± 0.12 (1.6–2.1)	1.8 ± 0.17 (1.6–2.1)
M3L	1.4 ± 0.07 (1.3–1.6)	1.5 ± 0.11 (1.3–1.8)	1.6 ± 0.21 (1.0–2.0)
mL	5.7 ± 0.44 (4.9–6.3)	6.3 ± 0.33 (5.7–6.8)	6.3 ± 0.20 (5.9–6.5)
m1L	2.1 ± 0.18 (1.8–2.3)	2.1 ± 0.11 (1.8–2.4)	2.1 ± 0.12 (1.8–2.4)
m2L	1.8 ± 0.19 (1.6–2.1)	1.8 ± 0.15 (1.6–2.1)	1.8 ± 0.14 (1.5–2.1)
m3L	1.6 ± 0.18 (1.3–1.8)	1.7 ± 0.16 (1.6–2.1)	1.7 ± 0.16 (1.6–2.1)

Table 2. The cranial measurements of laboratory bred *M. brandti* according to age groups. Means, ±: Standard deviation. N= Specimen numbers.

Table 3. Pairwise comparisons in cranial and dental measurements of *M. brandti* ( $\alpha= 0.05$ ). +=  $P < 0.05$ . - =  $P > 0.05$ .

Characteristics	Young - Adult	Young – Old	Adult – Old
ZB	+	+	+
IC	+	+	-
CBL	+	+	-
ONL	+	+	-
BL	+	+	+
NL	+	+	+
MAB	+	+	-
OW	+	+	+
DL	+	+	+
PL	+	+	+
IFL	+	+	+
MAL	+	+	+
UML	+	+	-
LFUM	-	-	-
LSUM	-	-	-
LTUM	+	+	-
LML	+	+	-
LFLM	-	-	-
LSLM	-	-	-
LTLM	-	+	+

statistically significant in young - adult and young – old pairwise comparisons ( $P < 0.05$ ) (Tables 2, 3). When adult measurements were compared to those of old animals, nine cranial characteristics (ZB, BL, NL, OW, DL, PL, IFL, MAL and m3L) were found to differ significantly (Table 3). Lyman and O'Brien (15) stated that young animals were weaned before the 20th day and the young were separated from the mother at the age of four weeks. These findings are consistent with those of Yiğit et al. (17). Yiğit et al. (17) stated that the total length, tail length, hind foot length and ear length of one-month-old animals were within the range of adults. However, Lyman and O'Brien (15) noted that animals born after June did not attain sexual maturity until the following spring. In the present study, animals did not attain sexual maturity at the age of four weeks, but their external and cranial measurements were within the range of adults. It is thus possible to pool the measurements of animals older than four weeks with those of adults. As a result, the animals younger than 30 days old with the third molars not erupting from their alveoli or with the third molar shorter than half of the second molar crown are referred to as young, and should not taken into account in taxonomic evaluations. In addition, cranial variations adult and old animals should not be considered taxonomic characteristics when comparing taxa.

## References

1. Ellerman, J.R. and Morrison-Scott, T.C.S., Checklist of Palaearctic and Indian Mammals 1758 to 1946. London: Brit. Mus. Nat. Hist., 810 pp., 1951.
2. Corbet, G.B., The Mammals of the Palaearctic Region: A Taxonomic Review. London, Brit. Mus. (Nat. Hist.), Cornell Univ. Press, 314 pp., 1978.
3. Harrison, D.L. and Bates, P.J.J., The Mammals of Arabia. Sec. Ed., Kent / England., Harr. Zool. Museum, 354 pp., 1991.
4. Wilson, D.E. and Reeder, D.A.M., Mammal Species of the World: A Taxonomic and Geographic Evidence. Second Ed. Smithsonian Institution Press, Washington and London, 1206 pp., 1993.
5. Mitchell-Jones, A.J., Amori, G., Bogdanowicz, W., Kry\_tufek, B., Reijnders, P.J.H., Spitzenberger, F., Stubbe, M., Thissen, J.B.M., Vohralik, V. and Zima, J., The Atlas of European Mammals. T & AD Poysen Ltd, London, 484 pp., 1999.
6. Nehring, A., Über *Cricetus*, *Cricetulus* und *Mesocricetus* n. subg. Zool. Anz., 21: 493-495, 1898.
7. Neuhäuser, G., Die Muriden von Kleinasien. Z. Säugetierkd. 11: 161-236, 1936.
8. Osborn, D.J., Rodents of subfamilies Murinae, Gerbillinae, and Cricetinae from Turkey. J. Egyptian Publ. Health Ass., 40: 401-421, 1965.
9. Hamar, M. and Schutowa, M., Neue Daten über die geographische Veränderlichkeit und die Entwicklung der Gattung *Mesocricetus* Nehring, 1898 (Glires, Mammalia). Z. Säugetierkd. 31: 237-251, 1966.
10. Steiner, H. and Vauk, G., Säugetiere aus dem Beyşehir Gebiet (Vilayet Konya, Kleinasien). Zool. Anz., 176: 97-102, 1966.
11. Lehmann, E. von., Eine neue Säugetieraufsammlung aus der Türkei im Museum Koenig. Zool. Beitr., 15: 299-327, 1969.
12. Sickenberg, O., Über das Vorkommen des Goldhamsters (*Mesocricetus auratus brandti* Nehring, 1898) in Zentralanatolien. Säugetierkd. Mitt., 19: 362-363, 1972.
13. Felten, H., Spitzenberger, F. and Storch, G., Zur Kleinsäugerfauna West-Anatoliens. Teil 1. Senckenberg. Biol., 52: 393-424, 1971.
14. Spitzenberger, F., Der Hamster *Mesocricetus brandti* (Nehring, 1898) in Zentralanatolien. Z. Säugetierkd. 37: 229-231, 1972.

15. Lyman, C.P. and O'Brien, R.C., Laboratory study of the Turkish Hamster *Mesocricetus brandti*. Breviora. Mus. Comp. Zool., Harvard University, Cambridge, 442: 1 – 27, 1977.
16. Dođramacı, S., Kefeliođlu, H. and Gündüz, İ., Karyological analysis of the species of *Mesocricetus* (Mammalia: Rodentia) in Anatolia. Tr. J. of Zoology, 18: 41-45, 1994 (in Turkish).
17. Yiđit, N., Çolak, E., Kivanç, E. and Sözen, M., Investigations on reproduction biology of *Mesocricetus brandti* (Nehring, 1898) (Mammalia: Rodentia) in Turkey. Tr. J. of Zoology, 21: 343-348, 1997 (in Turkish).
18. Yiđit, N., Çolak, E., Sözen, M., Özkurt, Ş. and Verimli, R., The distribution, morphology, and karyology of the genus *Mesocricetus* (Mammalia: Rodentia) in Turkey. Folia Zool., 49 (3): 167–174, 2000.
19. Harrison, D.L., The Mammals of Arabia: Lagomorpha and Rodentia. Vol. III. London: Ernest Bern. Ltd., 385 - 670 pp., 1972.