

## Papillary Carcinoma on the Thyroglossal Cyst Wall

Ş. Sinan KÜRKCÜOĞLU<sup>1</sup>  
Selahattin GENÇ<sup>1</sup>  
Ümit TUNÇEL<sup>1</sup>  
Funda DEMİRAGÇ<sup>2</sup>

**Abstract:** Thyroglossal duct cysts are usually located at the midline of the neck. While the coexistence of a carcinoma in a thyroglossal duct cyst is extremely rare, papillary carcinoma represents almost 80% of the cases. Its treatment is usually decided based on postoperative histopathological examinations. Although the Sistrunk procedure is often seen as adequate, the treatment of thyroglossal duct cysts remains controversial. In the present study, the Sistrunk procedure was used to excise a thyroglossal duct cyst in a 24-year-old female. Papillary carcinoma was confirmed with the histopathological examination following the surgery. We did not perform thyroidectomy, neck dissection or radioactive iodine treatment as carcinoma was limited to the cyst, no pathological findings were detected in the thyroid gland, and no palpable lymph node was found in the neck. No new clinicopathological problems arose in the two-year follow-up period.

**Key Words:** Thyroglossal duct cyst, papillary carcinoma

### Tiroglossal Kist Duvarında Gelişen Papiller Karsinoma

<sup>1</sup> Department of Otorhinolaryngology,  
Keçioren Education and  
Research Hospital,  
Ankara - TURKEY  
<sup>2</sup> Department of Pathology, S. B.  
Atatürk Chest Diseases and  
Surgery Education and  
Research Hospital,  
Ankara - TURKEY

**Özet:** Tiroglossal Ductus Kistleri boyun orta hattında sık görülen kitleler olmakla birlikte karsinomları oldukça nadirdir. Bu oran yaklaşık % 1-2 olup, % 80' i papiller karsinomdur. Tedavi çoğunlukla postoperatif histopatolojik incelemeyle konur. Genellikle "Sistrunk" prosedürü yeterlidir. Ancak tedavide halen tartışmalı konular mevcuttur. Biz de Tiroglossal Ductus Kisti tanısı koyduğumuz 24 yaşındaki bayan hastaya "Sistrunk" yaklaşımıyla kist eksizyonu yaptık. Papiller karsinom tanısını postoperatif olarak histopatolojik çalışmayla koyduk. Karsinomun kist içinde sınırlı olması, tiroid muayenesinde patoloji ve boyunda palpabl lenf nodu olmamasından dolayı tiroidektomi, boyun disseksiyonu ve radyoaktif iyot tedavisi yapmadık. Yaklaşık bir yıllık takiplerimizde de yeni bir klinikopatolojik probleme rastlamadık.

**Anahtar Sözcükler:** Tiroglossal Ductus Kisti, Papiller Karsinom

### Introduction

Thyroglossal cysts are the most common congenital masses that occur in the neck. The coexistence of a carcinoma in a thyroglossal duct (TGD) cyst is rather rare. Only 215 such cases have been reported in the relevant literature since 1911, indicating that it occurs in only 1-2% of all patients (1-4). Eighty percent of these malignant cases are diagnosed as papillary carcinoma. Their diagnosis, excluding the anaplastic type, is easy. They are seen most commonly in women between 20 and 50 years old. The main symptoms include a mass in the midline of the neck, occasional dysphagia, dyspnea and drainage from the sinus canal. It is generally treated using the Sistrunk procedure and sometimes by thyroidectomy and radioactive iodine treatment.

Received: March 27, 2008  
Accepted: August 28, 2008

### Case Report

A 24-year-old female patient with a six-month history of a midline neck mass was admitted to Keçioren Education and Research Hospital, Ear Nose and Throat Clinic. There were no other symptoms such as pain, redness, difficulty in swallowing, or voice or respiration problems. The physical examination of the patient revealed an approximately 1.5 × 1.5 cm midline neck mass at the hyoid bone level. It was mobile, normal by palpation, smooth, with clear boundaries, and elastic. Other ear, nose and throat examinations and the systemic examination revealed no other pathological findings. The patient was diagnosed with TGD cyst and surgery was recommended. The

#### Correspondence

Ş. Sinan KÜRKCÜOĞLU

Department of

Otorhinolaryngology,

Keçioren Research and

Training Hospital

Pınarbaşı Mah.,

Sanatoryum Cad. Ardahan Sok.

No: 1, Keçioren 06310

Ankara - TURKEY

drskurkuoglu@hotmail.com

preoperative thyroid scintigraphy showed that the thyroid gland was of normal size, the distribution of radioactive material on the gland was homogeneous and normal, the lobes had regular shape and edges, no nodes were detected, gland functions were normal, and no activity inhibition was seen in the submental area or thyroglossal canal localization. In the thyroid ultrasonography, the thyroid gland size was found to be normal, its contours were straight, its ECHO pattern was homogeneous and normal, and no lesions were found inside the gland causing border or ECHO difference.

The patient was treated with Sistrunk surgery. The cyst was approximately 3 × 2.5 × 2 cm, and the duct stretched as far as the hyoid bone and the base of the tongue. The cyst and its canal were excised together with the hyoid bone corpus as far as the base of the tongue. The pathological examination showed that the wall of the 3 × 2 × 1.5 cm cyst had thinned down to 1 mm at places, and that its lumen was full of a clear serous fluid. In the cross-sections coming from the pseudostratified epithelium-coated inner wall of the cyst, a tumor structure was seen branching towards the inside of the lumen, infiltrating the cyst wall in the shape of papillary structures, and containing psammoma mass. Follicles containing colloid were also seen in the cyst wall. In the immunohistochemical study, tumor cells were found to be keratin 7 (ScyTek, prediluted), HBME-1 (Neomarker, prediluted) and intranuclear TTF-1 positive. Using special stain, myosin was detected on the pseudostratified epithelium on the surface of the cyst (Figure). These histopathological findings were consistent with thyroid papillary carcinoma developed on the thyroglossal cyst wall. Upon the rather rare pathological diagnosis of

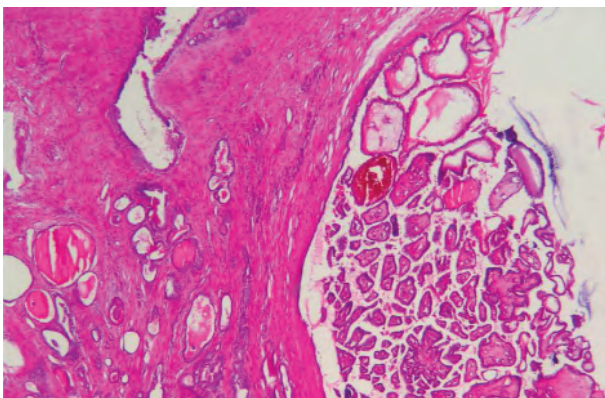


Figure. Papillary carcinoma on the thyroglossal cyst wall (HEX40).

thyroid papillary carcinoma in the thyroglossal canal, neck and thyroid ultrasonographies of the patient were repeated, but no neck masses or nodes in the thyroid gland were detected. Free T3, free T4 and TSH values were checked and no pathological values were found.

## Discussion

It is rather difficult to identify incidence of thyroid carcinoma and TGD cyst carcinoma because not all patients undergo total thyroidectomy together with the TGD cyst excision. It has also been suggested that total thyroidectomy does not lead to substantial change in patients with TGD cyst carcinoma. In the papillary carcinoma of TGD cysts, the rate of nodal metastasis has been reported around 10-15%. However, routine lymph node dissection is not performed (1-3). While excising the TGD cyst in our patient, we did not perform lymph node dissection or thyroidectomy.

In the 215 TGD cyst cases reported since 1911, the majority of the malignant tumors were observed to develop from the ectopic thyroid tissue in the cyst, and the most common type was found to be papillary carcinoma (4). Our case was papillary carcinoma as well, thus supporting the literature.

Weiss and Orlich (5) in their study found 11.4% TGD cyst carcinoma and microscopic carcinoma foci in the thyroid gland. They recommended total thyroidectomy following the histopathological diagnosis of papillary carcinoma in the cyst, even when the gland seemed normal in the initial surgery. Conversely, Kojima et al. (6) did not recommend total thyroidectomy in cases of clinical and intraoperative diagnosis of a normal thyroid gland.

Similarly, Patel et al. (1) did not recommend other treatments in low-risk patients (those below 45, with tumor diameter <4 cm, and no sign of extensive metastasis). Our patient was 24 and thus categorized as low-risk. Patel and Chu (4) also rejected the use of thyroidectomy when pathological findings were not present in the preoperative ultrasonographical and biochemical examinations, and when additional clinical pathological findings were absent.

Bosch and LiVolsi (7,8) stated that when the papillary carcinoma was entirely within the cyst, the Sistrunk procedure was adequate, but when the carcinoma had spread to the capsule of the cyst, wide resection and lymph node dissection were necessary.

According to Kristiansen (9) criteria, the Sistrunk procedure is sufficient when ectopic thyroid follicles are histologically present within the cyst, the tumor has not spread outside the cyst wall, the thyroid gland is normal, and cervical lymph nodes are not present. If one of these criteria is present, Kristiansen recommends thyroidectomy and additionally recommends neck dissection. We did not perform thyroidectomy on our patient as the papillary carcinoma was found to be restricted to the inside of the cyst in our postoperative histopathological examinations.

Katergiannakis et al. (10) emphasized in their study that TGD cysts are generally congenital and located at the level of the hyoid bone or lower. They found that the malignant transformation risk of TGD cysts was very low and often diagnosed via postoperative histopathological examinations. In our patient as well, TGD cyst diagnosis was finalized postoperatively through pathological examinations.

In conclusion, TGD cyst carcinomas are rare and are generally diagnosed postoperatively based on histopathological examinations. Its most common type is papillary carcinoma. If the ectopic thyroid follicles are within the cyst, the tumor has not spread along the cyst wall or protruded outside it, the thyroid gland seems normal, and no cervical lymph nodes are detected, the Sistrunk procedure is usually considered adequate. Nevertheless, more radical procedures such as total or subtotal thyroidectomy or radioactive iodine treatment may be necessary in some cases. As no pathological findings were obtained in our patient through the preoperative clinical and radiological examinations, we decided on the sole use of the Sistrunk procedure despite the postoperative histopathological diagnosis of papillary carcinoma. We followed the patient for two years, during which period no recurrence was seen.

## References

1. Patel SG, Escrig M, Shaha AR, Singh B, Shah JP. Management of well-differentiated thyroid carcinoma presenting within a thyroglossal duct cyst. *J Surg Oncol* 2002; 79: 134-9.
2. Allard RH. The thyroglossal cyst. *Head Neck Surg* 1982; 5: 134-46.
3. Van Vuuren PA, Balm AJ, Gregor RT, Hilgers FJ, Loftus BM, Delprat CC et al. Carcinoma arising in thyroglossal remnants. *Clin Otolaryngol* 1994; 19: 509-15.
4. Chu YC, Han JY, Han HS, Kim JM, Min SK, Kim YM. Primary papillary carcinoma arising in a thyroglossal duct cyst. *Yonsei Med J* 2002; 43: 381-4.
5. Weiss SD, Orlich CC. Primary papillary carcinoma of a thyroglossal duct cyst: report of a case and literature review. *Br J Surg* 1991; 78: 87-9.
6. Kojima Y, Sakata H, Nakamura Y, Furuya N. Papillary carcinoma of the thyroid originating in a thyroglossal cyst: report of a case and diagnostic criteria. *Otorhinolaryngol* 1996; 58: 238-41.
7. Bosch JLHR, Kummer EW, Hohmann FR. Carcinoma of the thyroglossal duct. *Neth J Surg* 1986; 38(2): 36-40.
8. LiVolsi VA, Perzin KH, Savetsky L. Carcinoma arising in median ectopic thyroid. *Cancer* 1974; 34: 1303-15.
9. Kristiansen S, Juul A, Moesner J. Thyroglossal cyst carcinoma. *J Laryngol Otol* 1984; 98: 1277-80.
10. Katergiannakis V, Manouras A, Tzardis P, Papadimitriou C, Apotolidis N. Thyroglossal duct cyst carcinoma report of two cases. *Am Surg* 1988; 54:315-7.